

## PART VII

# ONCOLOGY

### SECTION 1: PREVENTION

- 1.1. ANTIBIOTIC PROPHYLAXIS
- 1.2. CHEMOTHERAPY
- 1.3. RESEARCH CAVEATS
- 1.4. SURGICAL TECHNIQUE

### SECTION 2: TREATMENT

- 2.1. IRRIGATION AND DEBRIDEMENT
- 2.2. ONE-STAGE EXCHANGE
- 2.3. RESEARCH CAVEATS
- 2.4. TWO-STAGE EXCHANGE



## PREVENTION

## 1.1. PREVENTION: ANTIBIOTIC PROPHYLAXIS

**Authors:** Christina Gutowski, Michelle Ghert, Qiaojie Wang

**QUESTION 1:** Is there a correlation between operative time and the risk of subsequent surgical site infection/periprosthetic joint infection (SSI/PJI) in patients undergoing tumor resection and endoprosthetic reconstruction? If so, should postoperative antibiotics be prolonged in these patients?

**RECOMMENDATION:** Based largely on the arthroplasty literature, there is considerable evidence that prolonged operative time is associated with an increased risk for postoperative infection. However, there is insufficient evidence to suggest that a prolonged postoperative antibiotic regimen can mitigate this risk. Therefore, there is no evidence to support prolonged postoperative antibiotics in orthopaedic oncology patients undergoing surgeries of prolonged duration. If the duration of the procedure exceeds two half-lives of the prophylactic antimicrobial, intraoperative redosing is needed to ensure adequate serum and tissue concentrations of the antimicrobial.

**LEVEL OF EVIDENCE:** Moderate

**DELEGATE VOTE:** Agree: 100%, Disagree: 0%, Abstain: 0% (Unanimous, Strongest Consensus)

## RATIONALE

A thorough literature search was conducted using PubMed, Google Scholar and the Cochrane database. Search terms included “infection,” “surgical duration,” “surgical time,” “operative duration,” “orthopaedic,” “resection,” “reconstruction,” “endoprosthesis,” “antibiotic duration” and “postoperative antibiotic” in various combinations. The majority of articles found did not specifically focus on orthopaedic oncology patients.

Several studies support the hypothesis that prolonged surgical time was associated with increased risk of postoperative SSI. In a systematic review conducted by Cheng et al. [1], 4343 studies initially identified were narrowed down to 81, many of which demonstrated nearly double the infection risk in cases that exceeded cutoff times of 1-4 hours, and almost threefold the risk in surgeries exceeding 5 hours. When all included studies were pooled, the authors observed the risk of SSI to increase by 5% for every 10 minutes of surgery, 13% for every 15 minutes, 17% for every 30 minutes, and 37% for every 60 minutes. Based on the seven orthopaedic-specific studies included in their review, they found a statistically significant association between operative duration and infection with an 84% increased likelihood of SSI when operative time exceeded different cut-off points ( $p = 0.0003$ ).

In the arthroplasty literature, although some articles have demonstrated an association between prolonged operative time and increased risk of postoperative infection, it remains controversial whether increased operative time is an independent risk for SSI/PJI. Previous studies using administrative or registry databases have linked increased operative time to periprosthetic infection after total joint arthroplasty (TJA) with statistical significance [2-6]. However, the findings of these studies were limited by the significant heterogeneity of their samples and varying definitions for PJI as well as the definitions for operative time. Using data from a single institution, Peersman et al. [7] observed the risk of infection to increase significantly in total knee arthroplasty if the surgery took longer than 2.5 hours. They also investigated the impact of 24 vs. 48

hours of postoperative antibiotics on mitigating this increased risk and found no difference in the two antibiotic regimens. An epidemiological study of over 2,000 patients who underwent orthopaedic surgery in China also demonstrated that surgical time longer than three hours was an independent risk factor for development of SSI, with an odds ratio of 3.633 [8]. Pulido et al. corroborate these findings, showing that on univariate analysis longer operative time had statistically significant association with periprosthetic infection in 9,245 hip and knee replacement patients, but multivariate analysis adjusted for confounding factors revealed that operative time was not an independent predisposing factor for PJI [9]. In contrast, there are studies that failed to demonstrate such a correlation and even found an inverse relationship between operative time and PJI [10-14].

In the orthopaedic oncology patient, risks are even higher considering that patients are often immunocompromised and tumor resection can create a large dead space contributing to development of infection. The overall incidence of SSI in cases of malignant musculoskeletal tumors is reported as greater than 12% in some studies [15] and approximately 10% according to a large systematic review and meta-analysis [16]. Nagano et al. [15] demonstrated in their series of 457 patients with benign or malignant musculoskeletal tumors that duration of surgery is a significant risk factor in acquiring SSI (using threshold of 355 minutes), with an odds ratio of 6.06. Li et al. [17] reviewed a series of 53 patients with osteogenic sarcoma who underwent resection and segmental replacement, demonstrating a postoperative infection rate of 7.5%, much higher than primary arthroplasty. They utilized an antibiotic regimen consisting of three days of intravenous antibiotics followed by five days of oral antibiotics for all of the patients, and the authors were unsure whether this made a meaningful difference. In patients undergoing allograft reconstructions, the infection rate is also high: Tann and Mankin demonstrated a 9% infection rate in their series with the duration of the operative procedure to significantly increase the infection rate [18].

Surgeons have attempted to mitigate infection rates in high-risk patients by administering postoperative antibiotics for a prolonged period; largely, the efficacy of this strategy is not borne out in the literature. Aponte-Tinao et al. [19] report an overall infection rate of 9% in their series of 673 patients who underwent massive allograft reconstruction after tumor resection. Interestingly, a longer period of postoperative antibiotics was found to be a risk factor in development of infection. In the arthroplasty literature, there has also been no benefit associated with prolonged postoperative antibiotic use: Nelson et al. [20] argue that the optimal duration of antibiotics after surgery is 24 hours, as the risk of SSI did not decrease in their randomized controlled trial comparing that to a 7-day regimen. International Consensus Meeting on Periprosthetic Infections in 2013 recommended the use of 1 dose preoperatively and 24 hours of coverage postoperatively [21]. Although the Centers for Disease Control and Prevention recently released their 2017 Guideline for the Prevention of Surgical Site Infection [22], which recommends against the use of postoperative prophylactic antibiotics, including patients undergoing total joint arthroplasty, the American Association of Hip and Knee Surgeons (AAHKS) does not agree with this recommendation [23]. At this time, the AAHKS recommends postoperative antibiotics be continued for 24 hours and supports further research to determine whether shorter duration antibiotic treatment is safe and effective. Both the Board of Counselors and Board of Specialty Societies of the AAOS have endorsed this AAHKS recommendation through an advisory opinion; the American Academy of Orthopaedic Surgeons' Board of Directors adopted that advisory opinion in June 2017 [23]. In their comprehensive publication of clinical practice guidelines for antimicrobial prophylaxis in surgery, Bratzler et al. [24] recognize that duration of surgery is a risk factor for SSI but maintain the recommendation that the duration of postoperative antibiotics for orthopaedic procedures should be less than 24 hours. In cardiothoracic procedures in particular, the exception is made for a recommendation of up to 48 hours. Orthopaedic oncology patients undergoing prolonged surgical resection and reconstruction are not listed as an exception, despite their increased risks as outlined above. An ongoing large international randomized controlled trial, the Prophylactic Antibiotic Regimens in Tumor Surgery (PARITY) has published its feasibility pilot [25] and is scheduled to complete enrolment of 600 patients by the end of 2019 (NCT01479283). The study will determine if five days of postoperative antibiotics reduces infection rates compared to one day of postoperative antibiotics in the orthopaedic oncology population.

Although a longer period of postoperative antibiotics is not recommended by the guidelines [22–24], intraoperative redosing is needed to ensure adequate serum and tissue concentrations of the antimicrobial if the duration of the procedure exceeds two half-lives of the antimicrobial or there is excessive blood loss (i.e., > 1,500 mL). The redosing interval should be measured from the time of administration of the preoperative dose, not from the beginning of the procedure.

## REFERENCES

- [1] Cheng H, Chen BP, Soleas IM, Ferko NC, Cameron CG, Hinoul P. Prolonged operative duration increases risk of surgical site infections: a systematic review. *Surg Infect*. 2017;18:722–735.

- [2] Peersman G, Laskin R, Davis J, Peterson MGE, Richart T. Prolonged operative time correlates with increased infection rate after total knee arthroplasty. *HSS J*. 2006;2:70–72. doi:10.1007/s11420-005-0130-2.
- [3] Bozic KJ, Ward DT, Lau EC, Chan V, Wetters NG, Naziri Q, et al. Risk factors for periprosthetic joint infection following primary total hip arthroplasty: a case control study. *J Arthroplasty*. 2014;29:154–156. doi:10.1016/j.arth.2013.04.015.
- [4] Pugely AJ, Martin CT, Gao Y, Schweizer ML, Callaghan JJ. The incidence of and risk factors for 30-day surgical site infections following primary and revision total joint arthroplasty. *J Arthroplasty*. 2015;30:47–50. doi:10.1016/j.arth.2015.01.063.
- [5] Zhu Y, Zhang F, Chen W, Liu S, Zhang Q, Zhang Y. Risk factors for periprosthetic joint infection after total joint arthroplasty: a systematic review and meta-analysis. *J Hosp Infect*. 2015;89:82–89. doi:10.1016/j.jhin.2014.10.008.
- [6] Namba RS, Inacio MC, Paxton EW. Risk factors associated with deep surgical site infections after primary total knee arthroplasty: an analysis of 56,216 knees. *J Bone Joint Surg Am*. 2013;95:775–782. doi:10.2106/JBJS.L.00211.
- [7] Peersman G, Laskin R, Davis J, Peterson M. Infection in total knee replacement: a retrospective review of 6489 total knee replacements. *Clin Orthop Relat Res*. 2001;392:15–23.
- [8] Li G, Guo F, Ou Y, Dong G, Zhou W. Epidemiology and outcomes of surgical site infections following orthopedic surgery. *Am J Infect Control*. 2013;41:1268–1271.
- [9] Pulido L, Ghanem E, Joshi A, Purtill JJ, Parvizi J. Periprosthetic joint infection: the incidence, timing, and predisposing factors. *Clin Orthop Relat Res*. 2008;466:1710–1715. doi:10.1007/s11999-008-0209-4.
- [10] Boer ASD, Geubbels ELPE, Wille J, Groot AJM-D. Risk assessment for surgical site infections following total hip and total knee prostheses. *J Chemother*. 2001;13:42–47. doi:10.1179/joc.2001.13.Supplement-2.42.
- [11] Wymenga AB, Horn JR van, Theeuwes A, Tmuytjens HL, Slooff TJJH. Perioperative factors associated with septic arthritis after arthroplasty. *Acta Orthop Scand*. 1992;63:665–671. doi:10.1080/17453679209169732.
- [12] Suzuki G, Saito S, Ishii T, Motojima S, Tokuhashi Y, Ryu J. Previous fracture surgery is a major risk factor of infection after total knee arthroplasty. *Knee Surg Sports Traumatol Arthrosc*. 2011;19:2040–2044. doi:10.1007/s00167-011-1525-x.
- [13] Crowe B, Payne A, Evangelista PJ, Stachel A, Phillips MS, Slover JD, et al. Risk factors for infection following total knee arthroplasty: a series of 3836 cases from one institution. *J Arthroplasty*. 2015;30:2275–2278. doi:10.1016/j.arth.2015.06.058.
- [14] Naranje S, Lendway L, Mehle S, Gioe TJ. Does operative time affect infection rate in primary total knee arthroplasty? *Clin Orthop Relat Res*. 2015;473:64–69. doi:10.1007/s11999-014-3628-4.
- [15] Nagano S, Yokouchi M, Setoguchi T, Sasaki H, Shimada H, Kawamura I, et al. Analysis of surgical site infection after musculoskeletal tumor surgery: risk assessment using a new scoring system. *Sarcoma*. 2014;2014:645496.
- [16] Racano A, Pazonis T, Farrokhhyar F, Dehesi B, Ghert M. High infection rate outcomes in long-bone tumor surgery with endoprosthetic reconstruction in adults: a systematic review. *Clin Orthop Relat Res*. 2013;471:2017–2027. doi:10.1007/s11999-013-2842-9.
- [17] Li X, Moretti VM, Ashana AO, Lackman RD. Perioperative infection rate in patients with osteosarcomas treated with resection and prosthetic reconstruction. *Clin Orthop Relat Res*. 2011;469:2889–2894. doi:10.1007/s11999-011-1877-z.
- [18] Tan MH, Mankin HJ. Blood transfusion and bone allografts: effect on infection and outcome. *Clin Orthop Relat Res*. 1997;340:207–214.
- [19] Aponte-Tinao IA, Ayerza MA, Muscolo DL, Farfalli GL. What are the risk factors and management options for infection after reconstruction with massive bone allografts? *Clin Orthop Relat Res*. 2016;474:669–673.
- [20] Nelson CL, Green TG, Porter RA, Warren RD. One day versus seven days of preventive antibiotic therapy in orthopedic surgery. *Clin Orthop Relat Res*. 1983;258–263.
- [21] Parvizi J, Gehrke T, Chen AF. Proceedings of the International Consensus on Periprosthetic Joint Infection. *Bone Joint J*. 2013;95-B:1450–1452. doi:10.1302/0301-620X.95B11.33135.
- [22] Berrios-Torres SI, Umscheid CA, Bratzler DW, Leas B, Stone EC, Kelz RR, et al. Centers for Disease Control and Prevention Guideline for the Prevention of Surgical Site Infection, 2017. *JAMA Surg*. 2017;152:784–791. doi:10.1001/jamasurg.2017.0904.
- [23] Yates AJ. Postoperative prophylactic antibiotics in total joint arthroplasty. *Arthroplast Today*. 2018;4:130–131. doi:10.1016/j.artd.2018.01.003.
- [24] Bratzler DW, Dellinger EP, Olsen KM, Perl TM, Auwaerter PG, Bolon MK, et al. Clinical Practice Guidelines for Antimicrobial Prophylaxis in Surgery. *Surg Infect*. 2013;14:73–156. doi:10.1089/sur.2013.9999.
- [25] PARITY Investigators. Prophylactic antibiotic regimens in tumour surgery (PARITY): a pilot multicentre randomised controlled trial. *Bone Joint Res*. 2015;4:154–162. doi:10.1302/2046-3758.49.2000482.



Authors: Rodolfo Capanna, Ivan Boháček, Lorenzo Andreani

## QUESTION 2: Should factors like preoperative radiation, soft tissue vs. bone resection, presence of metal vs. structural allograft and other factors influence the dose and duration of antibiotic prophylaxis?

**RECOMMENDATION:** Unknown. Evidence and guidelines directing the prescription of prophylactic antibiotic regimens in musculoskeletal tumor surgery are lacking. Although long-term antibiotic prophylaxis may decrease the risk of deep infection, there is not sufficient evidence to recommend the use of anything other than routine antibiotic prophylaxis for patients undergoing major reconstruction.

**LEVEL OF EVIDENCE:** Limited

**DELEGATE VOTE:** Agree: 100%, Disagree: 0%, Abstain: 0% (Unanimous, Strongest Consensus)

### RATIONALE

Limb salvage and reconstruction using endoprostheses or bulk bone allografts have become standard of care for the management of bone tumors. In order to minimize peri- and postoperative risk for periprosthetic joint infection (PJI) development, antibiotic prophylaxis is routinely administered. While standard guidelines for primary total joint replacements exist and are widely accepted, there are no such guidelines/recommendations for reconstruction using endoprostheses or bulk bone allografts in orthopaedic tumor surgery. As a result, various opinions and variations exist between surgeons on the prescription of prophylactic antibiotic regimens in tumor surgery [1].

Duration of antibiotic prophylaxis remains one of the most important issues. For primary total joint replacement, consensus exists in that, postoperative antibiotics should not be administered for greater than 24 hours after surgery. However, oncologic patients represent a heterogeneous population which significantly differs from population of patients that undergo primary joint replacement, and different antibiotic regimes may be necessary.

There is considerable variation in the antibiotic regimens reported by available studies. Only seven studies specified the dose (i.e., 1 gm) and/or the type of prophylactic antibiotics administered (i.e., first-, second-, or third-generation gram-positive cephalosporin) [2–8]. Two studies specified giving additional coverage against gram-negative bacteria as well [5,6]. Twenty studies reported postoperative antibiotic regimens. These studies were subdivided into short-term regimens (0 to 24 hours of postoperative antibiotics) [2,3,7,9–12] and long-term regimens (greater than 24 hours of postoperative antibiotics) [4–6,8,13–21] and compared.

Several attempts were made in order to address this issue. A systematic review reported by Racano et al. (analyzing 4,838 patients included in 48 Level 4 studies) suggests that long-term antibiotic prophylaxis (pooled weighted infection rate 8%) is more effective than short-term prophylaxis (pooled weighted infection rate 13%) at minimizing infection in patients with lower extremity long-bone tumors that require surgery and endoprosthetic reconstruction [22]. Authors recognize limitations of the study, such as inconsistency in antibiotic prophylaxis used in each study, inconsistency in reporting applied regimens (only seven studies specified the dose and/or the type of antibiotics administered), majority were retrospective studies, and it was unclear whether the definition of infection is constant in all studies, since criteria changed over time [22]. These findings are important for two reasons. First, they support the notion that orthopaedic oncology patients are diverse populations who may require a diverse prophylactic regimen when compared to conventional arthroplasty patients. Second, these results reinforce the increasing need to limit infections and establish guidelines for antibiotic prophylaxis in tumor surgery.

In contrast, Aponte-Tinao concluded that prolonged periods of postoperative antibiotics were associated with a greater risk of infection. Other risk factors associated with increased infection rate were tibial allograft, male patients and procedures performed in conventional operating room [23].

Currently, there is an ongoing multicenter randomized controlled trial titled Prophylactic antibiotic regimens in tumor surgery (PARITY). This study includes a parallel two-arm design to investigate whether a 24-hour (short) or 5-day (long) antibiotic prophylaxis regimen should be implemented among patients undergoing surgical excision and endoprosthetic reconstruction of lower-extremity primary bone tumors [24]. The primary outcome is the rate of deep postoperative infections in each arm. Secondary outcomes include type and frequency of antibiotic-related adverse events, patient functional outcomes and quality-of-life scores, reoperation and mortality. Patients will be followed for one year after the procedure. The results of the final study are expected soon [25].

Unfortunately, there is insufficient literature to support alternate antibiotic regimens in patients who underwent preoperative radiation, patients who underwent soft tissue or bone resection, or patients who received a metal endoprosthesis or structural allograft after tumor resection. The main reason is poor reporting of the antibiotic regimens (dosage, duration, etc.), and therefore, all conclusions may be misleading. Even if this data were available, it would not be accurate to properly compare the infection rates of different clinical series based on their perioperative antibiotic protocols because of the heterogeneity of patient populations.

Since data on prophylactic antibiotic regimens are rather scarce, high quality, randomized controlled trials are needed for oncologic endoprosthesis or bulk bone allograft reconstructions in tumor orthopaedic surgery. As a result, the strength of the recommendation is limited.

### REFERENCES

- [1] Hasan K, Racano A, Deheshi B, Farrokhyar F, Wunder J, Ferguson P, et al. Prophylactic antibiotic regimens in tumor surgery (PARITY) survey. *BMC Musculoskelet Disord.* 2012;13:91. doi:10.1186/1471-2474-13-91.
- [2] Abudu A, Carter SR, Grimer RJ. The outcome and functional results of diaphyseal endoprostheses after tumour excision. *J Bone Joint Surg Br.* 1996;78:652–657.
- [3] Abudu A, Grimer RJ, Tillman RM, Carter SR. Endoprosthetic replacement of the distal tibia and ankle joint for aggressive bone tumours. *Int Orthop.* 1999;23:291–294.
- [4] Finstein JL, King JJ, Fox EJ, Ogilvie CM, Lackman RD. Bipolar proximal femoral replacement prostheses for musculoskeletal neoplasms. *Clin Orthop Relat Res.* 2007;459:66–75. doi:10.1097/BLO.0b013e31804f5474.
- [5] Gosheger G, Gebert C, Ahrens H, Streithueber A, Winkelmann W, Harges J. Endoprosthetic reconstruction in 250 patients with sarcoma. *Clin Orthop Relat Res.* 2006;450:164–171. doi:10.1097/01.blo.0000223978.36831.39.

- [6] Harges J, von Eiff C, Streitbuerger A, Balke M, Budny T, Henrichs MP, et al. Reduction of periprosthetic infection with silver-coated megaprotheses in patients with bone sarcoma. *J Surg Oncol*. 2010;101:389–395. doi:10.1002/jso.21498.
- [7] Jeys LM, Grimer RJ, Carter SR, Tillman RM. Periprosthetic infection in patients treated for an orthopaedic oncological condition. *J Bone Joint Surg Am*. 2005;87:842–849. doi:10.2106/JBJS.C.01222.
- [8] Li X, Moretti VM, Ashana AO, Lackman RD. Perioperative infection rate in patients with osteosarcomas treated with resection and prosthetic reconstruction. *Clin Orthop Relat Res*. 2011;469:2889–2894. doi:10.1007/s11999-011-1877-z.
- [9] Grimer RJ, Carter SR, Tillman RM, Sneath RS, Walker PS, Unwin PS, et al. Endoprosthetic replacement of the proximal tibia. *J Bone Joint Surg Br*. 1999;81:488–494.
- [10] Myers GJC, Abudu AT, Carter SR, Tillman RM, Grimer RJ. Endoprosthetic replacement of the distal femur for bone tumours: long-term results. *J Bone Joint Surg Br*. 2007;89:521–526. doi:10.1302/0301-620X.89B4.18631.
- [11] Myers GJC, Abudu AT, Carter SR, Tillman RM, Grimer RJ. The long-term results of endoprosthetic replacement of the proximal tibia for bone tumours. *J Bone Joint Surg Br*. 2007;89:1632–1637. doi:10.1302/0301-620X.89B12.19481.
- [12] Roberts P, Chan D, Grimer RJ, Sneath RS, Scales JT. Prosthetic replacement of the distal femur for primary bone tumours. *J Bone Joint Surg Br*. 1991;73:762–769.
- [13] Eckardt JJ, Eilber FR, Rosen G, Mirra JM, Dorey FJ, Ward WG, et al. Endoprosthetic replacement for stage IIB osteosarcoma. *Clin Orthop Relat Res*. 1991;202–213.
- [14] Morris HG, Capanna R, Del Ben M, Campanacci D. Prosthetic reconstruction of the proximal femur after resection for bone tumors. *J Arthroplasty*. 1995;10:293–299.
- [15] Ilyas I, Pant R, Kurar A, Moreau PG, Younge DA. Modular megaprosthesis for proximal femoral tumors. *Int Orthop*. 2002;26:170–173. doi:10.1007/s00264-002-0335-7.
- [16] Sharma S, Turcotte RE, Isler MH, Wong C. Cemented rotating hinge endoprosthesis for limb salvage of distal femur tumors. *Clin Orthop Relat Res*. 2006;450:28–32. doi:10.1097/01.blo.0000229316.66501.fc.
- [17] Sewell MD, Spiegelberg BGI, Hanna SA, Aston WJS, Bartlett W, Blunn GW, et al. Total femoral endoprosthetic replacement following excision of bone tumours. *J Bone Joint Surg Br*. 2009;91:1513–1520. doi:10.1302/0301-620X.91B11.21996.
- [18] Shekkeris AS, Hanna SA, Sewell MD, Spiegelberg BGI, Aston WJS, Blunn GW, et al. Endoprosthetic reconstruction of the distal tibia and ankle joint after resection of primary bone tumours. *J Bone Joint Surg Br*. 2009;91:1378–1382. doi:10.1302/0301-620X.91B10.22643.
- [19] Morii T, Yabe H, Morioka H, Beppu Y, Chuman H, Kawai A, et al. Postoperative deep infection in tumor endoprosthesis reconstruction around the knee. *J Orthop Sci*. 2010;15:331–339. doi:10.1007/s00776-010-1467-z.
- [20] Hanna SA, Sewell MD, Aston WJS, Pollock RC, Skinner JA, Cannon SR, et al. Femoral diaphyseal endoprosthetic reconstruction after segmental resection of primary bone tumours. *J Bone Joint Surg Br*. 2010;92:867–874. doi:10.1302/0301-620X.92B6.23449.
- [21] Bickels J, Wittig JC, Kollender Y, Henshaw RM, Kellar-Graney KL, Meller I, et al. Distal femur resection with endoprosthetic reconstruction: a long-term followup study. *Clin Orthop Relat Res*. 2002;225–235.
- [22] Racano A, Pazonis T, Farrokhyar F, Deheshi B, Ghert M. High infection rate outcomes in long-bone tumor surgery with endoprosthetic reconstruction in adults: a systematic review. *Clin Orthop Relat Res*. 2013;471:2017–2027. doi:10.1007/s11999-013-2842-9.
- [23] Aponte-Tinco LA, Ayerza MA, Muscolo DL, Farfalli GL. What are the risk factors and management options for infection after reconstruction with massive bone allografts? *Clin Orthop Relat Res*. 2016;474:669–673. doi:10.1007/s11999-015-4353-3.
- [24] Ghert M, Deheshi B, Holt G, Randall RL, Ferguson P, Wunder J, et al. Prophylactic antibiotic regimens in tumour surgery (PARITY): protocol for a multicentre randomised controlled study. *BMJ Open*. 2012;2(6):pii: e002197. doi:10.1136/bmjopen-2012-002197.
- [25] PARITY Investigators. Prophylactic antibiotic regimens in tumour surgery (PARITY): a pilot multicentre randomised controlled trial. *Bone Joint Res*. 2015;4:154–162. doi:10.1302/2046-3758.49.2000482.

Authors: Mitchell Schwaber, Yaakov Dickstein, Elizabeth Temkin

### QUESTION 3: Should patients with an oncologic endoprosthesis in place receive antibiotic prophylaxis during dental procedures?

**RECOMMENDATION:** Not routinely. Evidence-based guidelines by dentists and orthopaedic surgeons state that antibiotic prophylaxis is rarely appropriate for patients with prosthetic joints.

**LEVEL OF EVIDENCE:** Consensus.

**DELEGATE VOTE:** Agree: 100%, Disagree: 0%, Abstain: 0% (Unanimous, Strongest Consensus)

#### RATIONALE

The American Dental Association (ADA) [1] and the American Academy of Orthopaedic Surgeons (AAOS) [2,3] have issued updated guidelines regarding the need for antibiotic prophylaxis. The guidelines do not specifically address the topic of patients with an oncologic endoprosthesis. The guidelines are based on four case-control studies [4–7] that found no association between dental procedures and PJI and no effectiveness for antibiotic prophylaxis.

The ADA recommended that, “in general, for patients with prosthetic joint implants, prophylactic antibiotics are not recommended to prevent prosthetic joint infection.” Likewise, the AAOS recommended that “the practitioner might consider discontinuing the practice of routinely prescribing prophylactic antibiotics for patients with hip and knee prosthetic joint implants undergoing dental procedures.” The AAOS recommendations were more conservative than the ADA recommendations. The AAOS conducted a study using a modified Delphi procedure in which 14 experts were given scenarios involving patients with prosthetic joints and

voted whether antibiotic prophylaxis was appropriate. The panel concluded that prophylaxis may be warranted in the following situations: procedures involving manipulation of the gingival tissue or periapical region of teeth or perforation of the oral mucosa in patients who are severely immunocompromised and (1) have uncontrolled diabetes (glucose > 200 mg/dl, HbA<sub>1c</sub> > 8%), or (2) have controlled diabetes (glucose < 200 mg/dl, HbA<sub>1c</sub> < 8%) and have a history of periprosthetic joint infection (PJI) that required surgery or (3) do not have diabetes and have a history of PJI that required surgery and the initial joint replacement surgery was < 1 year ago.

The Dutch Orthopaedic and Dental Societies issued guidelines based on nine studies, all deemed to be very low quality. These guidelines advise that antibiotic prophylaxis should not be given to prevent PJI, regardless of the patient’s immune status.

Given the absence of studies in patients with an oncologic endoprosthesis, it seems prudent to apply the more moderate AAOS guidelines to this patient population.

## REFERENCES

- [1] Sollecito TP, Abt E, Lockhart PB, Truelove E, Paumier TM, Tracy SL, et al. The use of prophylactic antibiotics prior to dental procedures in patients with prosthetic joints: Evidence-based clinical practice guideline for dental practitioners—a report of the American Dental Association Council on Scientific Affairs. *J Am Dent Assoc.* 2015;146:11-16.e8. doi:10.1016/j.adaj.2014.11.012.
- [2] AAOS and ADA. Prevention of orthopaedic implant infection in patients undergoing dental procedures. Evidence-based guideline and evidence report. [https://www.aaos.org/uploadedFiles/PreProduction/Quality/Guidelines\\_and\\_Reviews/PUDP\\_guideline.pdf](https://www.aaos.org/uploadedFiles/PreProduction/Quality/Guidelines_and_Reviews/PUDP_guideline.pdf) 2012.
- [3] AAOS and ADA. Appropriate use criteria for the management of patients with orthopaedic implants undergoing dental procedures. <http://www.aaos.org/poiudpauc>. 2016.
- [4] Skaar DD, O'Connor H, Hodges JS, Michalowicz BS. Dental procedures and subsequent prosthetic joint infections: findings from the Medicare Current Beneficiary Survey. *J Am Dent Assoc.* 2011;142:1343-1351.
- [5] Swan J, Dowsey M, Babazadeh S, Mandaleson A, Choong PFM. Significance of sentinel infective events in haematogenous prosthetic knee infections. *ANZ J Surg.* 2011;81:40-45. doi:10.1111/j.1445-2197.2010.05486.x.
- [6] Barbari EF, Osmon DR, Carr A, Hanssen AD, Baddour LM, Greene D, et al. Dental procedures as risk factors for prosthetic hip or knee infection: a hospital-based prospective case-control study. *Clin Infect Dis* 2010;50:8-16. doi:10.1086/648676.
- [7] Jacobson JJ, Millard HD, Plezia R, Blankenship JR. Dental treatment and late prosthetic joint infections. *Oral Surg Oral Med Oral Pathol* 1986;61:413-417.



**Authors:** Mitchell Schwaber, Yaakov Dickstein, Elizabeth Temkin

## QUESTION 4: Should prophylactic antibiotics be started in patients with an oncologic endoprosthesis who develop neutropenia secondary to postoperative chemotherapy?

**RECOMMENDATION:** Not routinely. Evidence-based guidelines recommend limiting the routine use of prophylactic antibiotics to high-risk patients with chemotherapy-induced neutropenia.

**LEVEL OF EVIDENCE:** Consensus

**DELEGATE VOTE:** Agree: 100%, Disagree: 0%, Abstain: 0% (Unanimous, Strongest Consensus)

### RATIONALE

Guidelines published by the Infectious Diseases Society of America (IDSA) and the National Comprehensive Cancer Network (NCCN) recommend the use of fluoroquinolone prophylaxis during neutropenia in high-risk patients [1,2]. Risk stratification is based on a number of criteria, including malignancy type. According to IDSA guidelines, “Low-risk patients are those with neutropenia expected to resolve within 7 days and no active medical co-morbidity, as well as stable and adequate hepatic function and renal function. These low-risk features are most commonly found among patients with solid tumors” [1].

These recommendations are based on meta-analyses which included predominantly patients with hematological malignancy [3-5]. None of the articles included in the meta-analyses examined antibiotic prophylaxis in patients with primary bone malignancy or patients with an oncologic endoprosthesis. Furthermore, none of the articles specifically addressed cancer patients with foreign bodies. The largest and most comprehensive of the meta-analyses found that antibiotic prophylaxis reduces overall mortality versus placebo, with a number-needed-to-treat of 34 and low heterogeneity [4].

Two reasons limit the use of antibiotic prophylaxis in low-risk patients. First, concerns exist regarding the development of bacterial resistance and subsequent infection [2]. Although a meta-analysis found that fluoroquinolone prophylaxis leads to a non-significant increase in colonization with resistant bacteria with no difference in infections due to resistant bacteria, concerns remain [6]. Second, guidelines recommend treating low-risk patients with neutropenic fever as outpatients, with oral antibiotics including

fluoroquinolones on an outpatient basis. It is unclear whether the potential benefit of prophylactic quinolone use is greater than that of the use of these agents as treatment [2,7]. In summary, given the evidence to date, patients with an oncologic endoprosthesis should not routinely receive antibiotic prophylaxis during neutropenic episodes.

### REFERENCES

- [1] Freifeld AG, Bow EJ, Sepkowitz KA, Boeckh MJ, Ito JI, Mullen CA, et al. Clinical practice guideline for the use of antimicrobial agents in neutropenic patients with cancer: 2010 update by the Infectious Diseases Society of America. *Clin Infect Dis.* 2011;52:e56-93. doi:10.1093/cid/cir073.
- [2] National Comprehensive Cancer Network. NCCN clinical practice guidelines in oncology: prevention and treatment of cancer-related infections. Version 1. <https://www.nccn.org/> 2017.
- [3] Cruciani M, Rampazzo R, Malena M, Lazzarini L, Todeschini G, Messori A, et al. Prophylaxis with fluoroquinolones for bacterial infections in neutropenic patients: a meta-analysis. *Clin Infect Dis.* 1996;23:795-805.
- [4] Gafter-Gvili A, Fraser A, Paul M, van de Wetering M, Kremer L, Leibovici L. Antibiotic prophylaxis for bacterial infections in afebrile neutropenic patients following chemotherapy. *Cochrane Database Syst Rev.* 2005;CD004386. doi:10.1002/14651858.CD004386.pub2.
- [5] van de Wetering MD, de Witte MA, Kremer LCM, Offringa M, Scholten RJP, Caron HN. Efficacy of oral prophylactic antibiotics in neutropenic afebrile oncology patients: a systematic review of randomised controlled trials. *Eur J Cancer.* 2005;41:1372-1382. doi:10.1016/j.ejca.2005.03.006.
- [6] Gafter-Gvili A, Paul M, Fraser A, Leibovici L. Effect of quinolone prophylaxis in afebrile neutropenic patients on microbial resistance: systematic review and meta-analysis. *J Antimicrob Chemother.* 2007;59:5-22. doi:10.1093/jac/dkl425.
- [7] Taplitz RA, Kennedy EB, Bow EJ, Crews J, Gleason C, Hawley DK, et al. Outpatient management of fever and neutropenia in adults treated for malignancy: American Society of Clinical Oncology and Infectious Diseases Society of America Clinical Practice Guideline Update. *J Clin Oncol.* 2018;36:1443-1453. doi:10.1200/JCO.2017.77.6211.



Authors: Mitchell Schwaber, Yaakov Dickstein, Elizabeth Temkin

**QUESTION 5:** What type, dose and duration of prophylactic antibiotic(s) should be administered to patients undergoing oncologic endoprosthetic reconstruction who have received or will be receiving chemotherapy and/or radiation?

**RECOMMENDATION:** Antibiotic prophylaxis should be given in accordance with existing guidelines for standard arthroplasty surgery and other orthopaedic surgical procedures with foreign body placement.

**LEVEL OF EVIDENCE:** Consensus

**DELEGATE VOTE:** Agree: 93%, Disagree: 0%, Abstain: 7% (Super Majority, Strong Consensus)

**RATIONALE**

Studies examining the effect of chemotherapy and radiation on risk of postoperative infection in tumor patients have found an increased risk of surgical site infection (SSI) following radiation therapy (thoracic, head and neck, gynecological, breast malignancies) and chemotherapy (thoracic, head and neck, breast malignancies) [1,2]. No studies have been conducted to compare different prophylactic antibiotic regimens for patients who received radiation or chemotherapy prior to surgery; in a single randomized, controlled trial comparing prophylactic antibiotics with placebo in breast cancer patients, no significant difference was seen in the risk of developing postoperative infection between patients who received neoadjuvant chemotherapy and those who did not [3].

Studies examining the effect of chemotherapy and radiation on risk of postoperative infection specifically in patients with bone tumors and metastases have shown differing results based on the type and location of disease. A study of patients who underwent a variety of lower-extremity oncological operations did not find either chemotherapy or radiation to increase the risk of infection [4]. Similarly, in a cohort of patients undergoing surgery for primary bone tumor, mostly involving the lower limb, chemotherapy was not a risk factor for infection, nor was it in a group of patients who underwent endoprosthetic reconstruction for tumors around the knee [5,6]. On the other hand, a study of patients with spinal metastases found that postoperative radiation was associated with increased risk of infection [7].

As no studies have been conducted addressing the tailoring of antibiotic prophylaxis in oncologic patients undergoing tumor surgery pre- or post-radiation or chemotherapy, including endopros-

thetic reconstruction, prophylaxis should be given in accordance with existing guidelines for arthroplasty and other orthopaedic surgical procedures with foreign body placement [1,8]. In the event of colonization with methicillin-resistant *Staphylococcus aureus*, the choice of intravenous antimicrobial prophylactic agent should be adjusted accordingly.

**REFERENCES**

- [1] Bratzler DW, Dellinger EP, Olsen KM, Perl TM, Auwaerter PG, Bolon MK, et al. Clinical practice guidelines for antimicrobial prophylaxis in surgery. *Surg Infect.* 2013;14:73-156. doi:10.1089/sur.2013.9999.
- [2] Jones DJ, Bunn F, Bell-Syer SV. Prophylactic antibiotics to prevent surgical site infection after breast cancer surgery. *Cochrane Database Syst Rev.* 2014;CD005360. doi:10.1002/14651858.CD005360.pub4.
- [3] Bold RJ, Mansfield PF, Berger DH, Pollock RE, Singletary SE, Ames FC, et al. Prospective, randomized, double-blind study of prophylactic antibiotics in axillary lymph node dissection. *Am J Surg.* 1998;176:239-243.
- [4] Morris CD, Sepkowitz K, Fonshell C, Margetson N, Eagan J, Miransky J, et al. Prospective identification of risk factors for wound infection after lower extremity oncologic surgery. *Ann Surg Oncol.* 2003;10:778-782.
- [5] Miwa S, Shirai T, Yamamoto N, Hayashi K, Takeuchi A, Tada K, et al. Risk factors for postoperative deep infection in bone tumors. *PloS One.* 2017;12:e0187438. doi:10.1371/journal.pone.0187438.
- [6] Morii T, Yabe H, Morioka H, Beppu Y, Chuman H, Kawai A, et al. Postoperative deep infection in tumor endoprosthesis reconstruction around the knee. *J Orthop Sci.* 2010;15:331-339. doi:10.1007/s00776-010-1467-z.
- [7] Demura S, Kawahara N, Murakami H, Nambu K, Kato S, Yoshioka K, et al. Surgical site infection in spinal metastasis: risk factors and countermeasures. *Spine.* 2009;34:635-639. doi:10.1097/BRS.0b013e31819712ca.
- [8] Berríos-Torres SI, Umscheid CA, Bratzler DW, Leas B, Stone EC, Kelz RR, et al. Centers for Disease Control and Prevention Guideline for the prevention of surgical site infection, 2017. *JAMA Surg.* 2017;152:784-791. doi:10.1001/jamasurg.2017.0904.



Authors: Mitchell Schwaber, Yaakov Dickstein, Elizabeth Temkin

**QUESTION 6:** Does the type, dose, and duration of antibiotic prophylaxis differ for patients undergoing oncologic endoprosthetic reconstruction compared to conventional total joint arthroplasty (TJA)?

**RECOMMENDATION:** No. There is no recommendation to adjust type, dose or duration of antibiotic prophylaxis in patients undergoing oncologic endoprosthetic reconstruction from that which is routinely administered in conventional TJA.

**LEVEL OF EVIDENCE:** Consensus

**DELEGATE VOTE:** Agree: 93%, Disagree: 0%, Abstain: 7% (Super Majority, Strong Consensus)



## RATIONALE

Rates of infectious complications following knee and hip arthroplasty are generally less than 2% [1]. However, rates of infectious complications following lower-extremity limb salvage therapy with endoprostheses are approximately 10% [2]. The reason for this difference remains unclear, possibly due to systemic factors not directly related to the presence of localized malignancy [3].

Preoperative parenteral antibiotics have been demonstrated to reduce wound infections following TJA [4]. In a meta-analysis of antibiotic prophylaxis in TJA, which included 7 studies with 3,065 participants, the relative risk of infection was reduced by 81% compared to placebo [4]. None of the studies included in the meta-analysis or accompanying systematic review specifically addressed prophylaxis in patients undergoing orthopaedic endoprosthetic reconstruction.

Based on the preponderance of evidence, clinical guidelines recommend the use of perioperative parenteral antibiotics before TJA and other orthopaedic surgeries with foreign body placement [5,6]. No data exist regarding the tailoring of prophylaxis in oncologic patients with endoprosthetic reconstruction. Therefore, antibiotics should be given in accordance with accepted regimens.

## REFERENCES

- [1] Edwards JR, Peterson KD, Mu Y, Banerjee S, Allen-Bridson K, Morrell G, et al. National Healthcare Safety Network (NHSN) report: data summary for 2006 through 2008, issued December 2009. *Am J Infect Control*. 2009;37:783–805. doi:10.1016/j.ajic.2009.10.001.
- [2] Racano A, Pazonis T, Farrokhyar F, Deheshi B, Ghert M. High infection rate outcomes in long-bone tumor surgery with endoprosthetic reconstruction in adults: a systematic review. *Clin Orthop Relat Res*. 2013;471:2017–2027. doi:10.1007/s11999-013-2842-9.
- [3] Barbari EF, Hanssen AD, Duffy MC, Steckelberg JM, Ilstrup DM, Harmsen WS, et al. Risk factors for prosthetic joint infection: case-control study. *Clin Infect Dis*. 1998;27:1247–1254.
- [4] AlBuhairan B, Hind D, Hutchinson A. Antibiotic prophylaxis for wound infections in total joint arthroplasty: a systematic review. *J Bone Joint Surg Br*. 2008;90:915–919. doi:10.1302/0301-620X.90B7.20498.
- [5] Bratzler DW, Dellinger EP, Olsen KM, Perl TM, Auwaerter PG, Bolon MK, et al. Clinical practice guidelines for antimicrobial prophylaxis in surgery. *Surg Infect (Larchmt)*. 2013;14:73–156. doi:10.1089/sur.2013.9999.
- [6] Berrios-Torres SI, Umscheid CA, Bratzler DW, Leas B, Stone EC, Kelz RR, et al. Centers for Disease Control and Prevention Guideline for the prevention of surgical site infection, 2017. *JAMA Surg*. 2017;152:784–791. doi:10.1001/jamasurg.2017.0904.



## 1.2. PREVENTION: CHEMOTHERAPY

**Authors:** R. Lor Randall, Brian M. Smith, Karan Goswami, John S. Groundland, Antonios I. Papadopoulos, Panayiotis J. Papagelopoulos

### QUESTION 1: Do we need to evaluate the gut and skin microbiome of patients after chemotherapy to assess the risk for potential infection after endoprosthetic reconstruction?

**RECOMMENDATION:** Unknown. There is no evidence in the literature to suggest that evaluation of the gut and/or skin microbiome following chemotherapy aids with risk stratification for potential infection in patients undergoing endoprosthetic limb salvage surgery.

**LEVEL OF EVIDENCE:** Consensus

**DELEGATE VOTE:** Agree: 100%, Disagree: 0%, Abstain: 0% (Unanimous, Strongest Consensus)

## RATIONALE

In the orthopaedic oncology literature, infection rates following metallic endoprosthesis limb salvage surgery are high and vary from 2.2–34% [1–4]. In a systematic review of the literature, Henderson et al. found the overall rate of infection-related failure of endoprostheses to be 7.8% and infection as the most common mode of failure in their current investigation of primary endoprostheses. Proximal tibia replacements and total femur replacements were noted to be at particular risk, requiring infection-related revision surgery in 19.7% and 17.5% of cases, respectively [1].

While not fully understood or rigorously investigated, the causes of these high rates of infection are likely multi-factorial, including extensive surgical dissection and resection, increased operation time, substantial loss of blood, inadequate soft tissue coverage, implantation of large constructs with foreign material and, often in the case of oncology patients, a poor nutritional and compromised immune status [5].

Perioperative chemotherapy has been shown to increase the total revision rates of endoprosthetic reconstruction to 40% from 10% due to its reduction of osseointegration [6]. The impact of chemo-

therapy on the rates of infection following endoprosthetic reconstruction remains unclear. There are conflicting reports on whether immunological deficiency following chemotherapy is a risk for postoperative infection of endoprostheses. In a review, Kapoor and Thiyam documented that a compromised immune status after neoadjuvant chemotherapy may result in postsurgical infection having an increased infection rate of 20% [5]. While in a multicenter retrospective review, Morii et al. showed chemotherapy did not affect infection risk and suggested no drawbacks related to chemotherapy in regards to postoperative infection control of endoprostheses [2]. It was shown that some patients who developed infection during postoperative chemotherapy were controlled by amelioration of myelosuppression alone, while others required revision and antibiotic therapy [7].

Any measure that leads to decreased infection rates of metallic endoprosthesis reconstruction would be desirable. Given the prevalence of the problem and the severity of the consequences of deep infection, even weak evidence supporting a decrease in postoperative infection rates would be worth considering. While a few interven-

tions have been noted to be beneficial, as reported in retrospective case series, no rigorous, prospective studies have been completed in this population. In regard to the question above, there is no evidence (level I, II, III or IV) to support or reject evaluation of the skin or gut microbiome after neoadjuvant or adjuvant chemotherapy.

Conceptually, chemotherapy is known to alter the gut microbiome, which likely influences the development and manifestations of chemotherapy-associated mucositis [8–10]. When undergoing induction chemotherapy for acute myeloid leukemia, patients who developed infection after treatment were shown to have significantly lower baseline stool bacteria diversity and the therapy itself was shown to decrease microbiome diversity [11]. Taxonomic shifts in the gut biome have been demonstrated in lymphoma patients following chemotherapy, with decreases in Firmicutes (species including *Staphylococcus*, *Streptococcus*, *Enterococcus*) and Actinobacteria (*Streptomyces*, *Propionibacteria*) and increases in Proteobacteria (*Escherichia*, *Salmonella*, *Vibrio*, *Helicobacter*, *Yersinia*, *Legionellales*) [8]. In a pediatric study of acute lymphoblastic leukemia (ALL), the abundance of Proteobacteria in the gut microbiome before chemotherapy was predictive of the infection risk and domination of the gut by *Enterococcaceae* or *Streptococcaceae* during current and subsequent phases of chemotherapy [12]. Decreased diversity in the taxa of the gut microbiome has been used as a predictive tool for chemotherapy-related bloodstream infection risk [13]. Chemotherapy alters the skin microbiome in that fungal infections are common during and following chemotherapy [14].

Despite these documented changes in the microbiome of the gut and on the skin and their relation to infection risk, there is no proven association or theoretical link with postoperative endoprosthetic infection. This is illustrated in two ways. First, the causative organisms of endoprosthetic infection are those typically found in postoperative periprosthetic joint infections (e.g., *Staphylococcus*, *Streptococcus*, *Enterococcus*, *Pseudomonas* species) [2,7,15], which are not species noted to increase following chemotherapy (e.g., *Proteobacteria* and *Fungi*) [8]. Second, the average time to infection-related surgical revision of endoprostheses is 47 months following index endoprosthesis placement [1]. This timeline is long after chemotherapy has been completed and more than enough time for chemotherapy-induced changes in the diversity of the gut and skin microbiome to return to normal.

There is still a need for further research to clarify whether skin and gut microbiome testing would prove useful in risk stratification for infection following endoprosthetic reconstruction.

## REFERENCES

- [1] Henderson ER, et al. Failure mode classification for tumor endoprostheses: retrospective review of five institutions and a literature review. *J Bone Joint Surg Am.* 2011;93(5):418–429.
- [2] Morii T, Yabe H, Morioka H, Beppu Y, Chuman H, Kawai A, et al. Postoperative deep infection in tumor endoprosthesis reconstruction around the knee. *J Orthop Sci.* 2010;15:331–339. doi:10.1007/s00776-010-1467-z.
- [3] Nobile M, Navone P, Domeniconi G, Della Valle A, Daolio PA, Buccino NA, et al. Surgical site infections in oncologic orthopaedic prosthetics surgery. *Ann Ig.* 2015;27:711–717.
- [4] Haijie L, Dasen L, Tao J, Yi Y, Xiaodong T, Wei G. Review: implant survival and complication profiles of endoprostheses for treating tumor around the knee in adults: a systematic review of the literature over the past 30 years. *J Arthroplasty.* 2018;33:1275–1287.e3. doi:10.1016/j.arth.2017.10.051.
- [5] Kapoor SK, Thiyyam R. Management of infection following reconstruction in bone tumors. *J Clin Orthop Trauma.* 2015;6:244–251. doi:10.1016/j.jcot.2015.04.005.
- [6] Pugh LR, Clarkson PW, Phillips AE, Biau DJ, Masri BA. Tumor endoprosthesis revision rates increase with peri-operative chemotherapy but are reduced with the use of cemented implant fixation. *J Arthroplasty.* 2014;29:1418–1422. doi:10.1016/j.arth.2014.01.010.
- [7] Morii T, Morioka H, Ueda T, Araki N, Hashimoto N, Kawai A, et al. Deep infection in tumor endoprosthesis around the knee: a multi-institutional study by the Japanese musculoskeletal oncology group. *BMC Musculoskel Disord.* 2013;14:51. doi:10.1186/1471-2474-14-51.
- [8] Montassier E, et al. Chemotherapy-driven dysbiosis in the intestinal microbiome. *Aliment Pharmacol Ther.* 2015; 42(5):515–528.
- [9] Bai J, Behera M, and Bruner DW. The gut microbiome, symptoms, and targeted interventions in children with cancer: a systematic review. *Support Care Cancer.* 2018;26(2):427–439.
- [10] Nycz BT, et al. Evaluation of bloodstream infections, *Clostridium difficile* infections, and gut microbiota in pediatric oncology patients. *PLoS One.* 2018;13(1):e0191232.
- [11] Galloway-Peña JR, Smith DP, Sahasrabhojane P, Ajami NJ, Wadsworth WD, Daver NG, et al. The role of the gastrointestinal microbiome in infectious complications during induction chemotherapy for acute myeloid leukemia: microbiome analyses of patients with AML. *Cancer.* 2016;122:2186–2196. doi:10.1002/cncr.30039.
- [12] Hakim H, Dallas R, Wolf J, Tang L, Schultz-Cherry S, Darling V, et al. Gut microbiome composition predicts infection risk during chemotherapy in children with acute lymphoblastic leukemia. *Clin Infect Dis.* 2018. doi:10.1093/cid/ciy153.
- [13] Montassier E, Al-Ghalith GA, Ward T, Corvec S, Gastinne T, Potel G, et al. Pretreatment gut microbiome predicts chemotherapy-related bloodstream infection. *Genome Med.* 2016;8. doi:10.1186/s13073-016-0301-4.
- [14] Teoh F, and Pavelka N. How chemotherapy increases the risk of systemic Candidiasis in cancer patients: current paradigm and future directions. *Pathogens.* 2016;5(1):pii:e6.
- [15] Harges J, Henrichs M-P, Gosheger G, Guder W, Nottrott M, Andreou D, et al. Tumour endoprosthesis replacement in the proximal tibia after intra-articular knee resection in patients with sarcoma and recurrent giant cell tumour. *Int Orthop.* 2018. doi:10.1007/s00264-018-3893-z.

**Authors:** Andreas F. Mavrogenis, Takeshi Morii, Jorge Manrique

## QUESTION 2: Should an absolute neutrophil count of $> 1000/\text{mm}^3$ be the minimum for patients undergoing limb salvage surgery after receiving chemotherapy?

**RECOMMENDATION:** Yes. An absolute neutrophil count of  $>1000/\text{mm}^3$  should be the minimum for patients undergoing limb salvage surgery after receiving chemotherapy.

**LEVEL OF EVIDENCE:** Consensus

**DELEGATE VOTE:** Agree: 100%, Disagree: 0%, Abstain: 0% (Unanimous, Strongest Consensus)

## RATIONALE

Neutropenia has been defined as an absolute neutrophil count (ANC) of  $1500/\text{mm}^3$  or lower [1]. Historically, this cutoff value has been considered as a risk factor for developing infections and complications. Bodey et al. [2] initially described this association.

They observed that the infection rate in patients with ANC below  $1000/\text{mm}^3$  was 14% and below  $100/\text{mm}^3$  up to 60% [2]. Furthermore, lower ANC levels have been identified as an independent risk factor for infections [3]. This latter publication also demonstrated that the

risk gradually increases as ANC decreases. In a more recent study, Lima et al. [4] evaluated patients with ANC levels less than or equal to 500 cells/mm<sup>3</sup> further support this relationship.

Different chemotherapeutic agents are used in the treatment of bone and soft tissue sarcomas. Some have shown to be myelosuppressive and thus reduce the ANC [5]. This is also one of the most critical criteria to administering chemotherapeutic regimens as it has been directly associated with an increased risk of complications [3,6]. The combination of wide resection and neo-adjuvant/adjuvant chemotherapy is a standard treatment modality for bone sarcomas [7]. The combination of methotrexate (MTX), doxorubicin (ADR), cisplatin (CDDP) and ifosfamide (I) are agents used for conventional osteosarcoma [7–11]. For small round cell sarcoma including Ewing's sarcoma, multi-agent chemotherapy with vincristine-doxorubicin-cyclophosphamide, ifosfamide-etoposide (VDC-IE) is used [12,13]. Chemotherapy for high-grade non-round cell, soft tissue sarcoma is controversial, but the effectiveness of chemotherapy for such sarcomas has been shown in several studies [14–20]. The conventional key drugs for such condition include ADR and I [14,15,17]. In addition, dacarbazine (DTIC), gemcitabine (G) and docetaxel (D) became the options for soft tissue sarcomas [20–24]. Recent innovation in this area provided additional reagents including pazopanib, trabectedin and eribulin, which are mainly used as second line treatment for advanced soft tissue sarcomas [25–31].

When evaluating patients with low ANC undergoing surgical interventions, these patients also exhibit an increased risk of surgical site infection compared to patients with normal counts. Natour et al. [32] evaluated patients undergoing abdominal surgery in the setting of neutropenia. They categorized patients with ANC < 500/mm<sup>3</sup>, between 500/mm<sup>3</sup> and 1000/mm<sup>3</sup>, and between 1000/mm<sup>3</sup> and 1500/mm<sup>3</sup>. Patients with lower ANC also exhibited higher postoperative infection rates, hospital stay and mortality. A relatively recent study evaluated the risk for infection of implantable port devices in pediatric oncology patients [33]. Again, patients with low ANCs had higher infection rates compared to those with normal ANC.

No study was identified that directly associates infection risk in patients undergoing limb salvage and low ANC. Given that limb salvage surgery is a complex procedure, all efforts to avoid infection should be undertaken. Based on the available literature, we consider that patients with an ANC below 1000/mm<sup>3</sup>, either from the chemotherapy or the solid tumor itself, should not undergo limb salvage surgery until ANC is above 1000/mm<sup>3</sup> and possibly above 1500/mm<sup>3</sup>.

## REFERENCES

- Newburger PE, Dale DC. Evaluation and management of patients with isolated neutropenia. *Semin Hematol.* 2013;50:198–206. doi:10.1053/j.seminhematol.2013.06.010.
- Bodey GP, Buckley M, Sathe YS, Freireich EJ. Quantitative relationships between circulating leukocytes and infection in patients with acute leukemia. *Ann Intern Med.* 1966;64:328–340.
- Rosenfeld SI. Neutropenia: an analysis of the risk factors for infection. *Yale Med Thesis Digit Libr.* 1980;3087.
- Lima SS, França MS, Godoi CC, Martinho GH, de Jesus LA, Romanelli RM, et al. Neutropenic patients and their infectious complications at a University Hospital. *Rev Bras Hematol Hemoter.* 2013;35:18–22. doi:10.5581/1516-8484.20130009.
- Vadhan-Raj S, Broxmeyer HE, Hittelman WN, Papadopoulos NE, Chawla SP, Fenoglio C, et al. Abrogating chemotherapy-induced myelosuppression by recombinant granulocyte-macrophage colony-stimulating factor in patients with sarcoma: protection at the progenitor cell level. *J Clin Oncol.* 1992;10:1266–1277. doi:10.1200/JCO.1992.10.8.1266.
- Boxer L, Dale DC. Neutropenia: causes and consequences. *Semin Hematol.* 2002;39:75–81.
- Biermann JS, Chow W, Reed DR, Lucas D, Adkins DR, Agulnik M, et al. NCCN Guidelines Insights: bone cancer, Version 2.2017. *J Natl Compr Canc Netw.* 2017;15:155–167.
- Iwamoto Y, Tanaka K, Isu K, Kawai A, Tatezaki S, Ishii T, et al. Multiinstitutional phase II study of neoadjuvant chemotherapy for osteosarcoma (NECO study) in Japan: NECO-93 and NECO-95. *J Orthop Sci.* 2009;14:397–404. doi:10.1007/s00776-009-1347-6.
- Iwamoto Y, Tanaka K. The activity of the Bone and Soft Tissue Tumor Study Group of the Japan Clinical Oncology Group. *Jpn J Clin Oncol.* 2012;42:467–470. doi:10.1093/jjco/hys059.
- Ferrari S, Ruggieri P, Cefalo G, Tamburini A, Capanna R, Fagioli F, et al. Neoadjuvant chemotherapy with methotrexate, cisplatin, and doxorubicin with or without ifosfamide in nonmetastatic osteosarcoma of the extremity: an Italian sarcoma group trial ISG/OS-1. *J Clin Oncol.* 2012;30:2112–2118. doi:10.1200/JCO.2011.38.4420.
- Marina NM, Smeland S, Bielack SS, Bernstein M, Jovic G, Krailo MD, et al. Comparison of MAPIE versus MAP in patients with a poor response to preoperative chemotherapy for newly diagnosed high-grade osteosarcoma (EURAMOS-1): an open-label, international, randomised controlled trial. *Lancet Oncol.* 2016;17:1396–1408. doi:10.1016/S1470-2045(16)30214-5.
- Fox E, Widemann BC, Hawkins DS, Jayaprakash N, Dagher R, Aikin AA, et al. Randomized trial and pharmacokinetic study of pegfilgrastim versus filgrastim after dose-intensive chemotherapy in young adults and children with sarcomas. *Clin Cancer Res.* 2009;15:7361–7367. doi:10.1158/1078-0432.CCR-09-0761.
- Spunt SL, Irving H, Frost J, Sender L, Guo M, Yang B-B, et al. Phase II, randomized, open-label study of pegfilgrastim-supported VDC/IE chemotherapy in pediatric sarcoma patients. *J Clin Oncol.* 2010;28:1329–1336. doi:10.1200/JCO.2009.24.8872.
- Nielsen OS, Judson I, van Hoesel Q, le Cesne A, Keizer HJ, Blay JY, et al. Effect of high-dose ifosfamide in advanced soft tissue sarcomas. A multicentre phase II study of the EORTC Soft Tissue and Bone Sarcoma Group. *Eur J Cancer.* 2000;36:61–67.
- Woll PJ, Reichardt P, Le Cesne A, Bonvalot S, Azzarelli A, Hoekstra HJ, et al. Adjuvant chemotherapy with doxorubicin, ifosfamide, and lenograstim for resected soft-tissue sarcoma (EORTC 62931): a multicentre randomised controlled trial. *Lancet Oncol.* 2012;13:1045–1054. doi:10.1016/S1470-2045(12)70346-7.
- Gronchi A, Frustaci S, Mercuri M, Martin J, Lopez-Pousa A, Verderio P, et al. Short, full-dose adjuvant chemotherapy in high-risk adult soft tissue sarcomas: a randomized clinical trial from the Italian Sarcoma Group and the Spanish Sarcoma Group. *J Clin Oncol.* 2012;30:850–856. doi:10.1200/JCO.2011.37.7218.
- Judson I, Verweij J, Gelderblom H, Hartmann JT, Schöffski P, Blay JY, et al. Doxorubicin alone versus intensified doxorubicin plus ifosfamide for first-line treatment of advanced or metastatic soft-tissue sarcoma: a randomised controlled phase 3 trial. *Lancet Oncol.* 2014;15:415–423. doi:10.1016/S1470-2045(14)70063-4.
- Tanaka K, Mizusawa J, Fukuda H, Araki N, Chuman H, Takahashi M, et al. Perioperative chemotherapy with ifosfamide and doxorubicin for high-grade soft tissue sarcomas in the extremities (JCOG0304). *Jpn J Clin Oncol.* 2015;45:555–561. doi:10.1093/jjco/hyv042.
- von Mehren M, Randall RL, Benjamin RS, Boles S, Bui MM, Conrad EU, et al. Soft tissue sarcoma, Version 2.2016, NCCN Clinical Practice Guidelines in Oncology. *J Natl Compr Canc Netw.* 2016;14:758–786.
- Bui-Nguyen B, Ray-Coquard I, Chevreau C, Penel N, Bay JO, Coindre JM, et al. High-dose chemotherapy consolidation for chemosensitive advanced soft tissue sarcoma patients: an open-label, randomized controlled trial. *Ann Oncol.* 2012;23:777–784. doi:10.1093/annonc/mdr282.
- Kataoka K, Tanaka K, Mizusawa J, Kimura A, Hiraga H, Kawai A, et al. A randomized phase II/III trial of perioperative chemotherapy with adriamycin plus ifosfamide versus gemcitabine plus docetaxel for high-grade soft tissue sarcoma: Japan Clinical Oncology Group Study JCOG1306. *Jpn J Clin Oncol.* 2014;44:765–769. doi:10.1093/jjco/hyu080.
- Seddon B, Strauss SJ, Whelan J, Leahy M, Woll PJ, Cowie F, et al. Gemcitabine and docetaxel versus doxorubicin as first-line treatment in previously untreated advanced unresectable or metastatic soft-tissue sarcomas (GeDDiS): a randomised controlled phase 3 trial. *Lancet Oncol.* 2017;18:1397–1410. doi:10.1016/S1470-2045(17)30622-8.
- García-Del-Muro X, López-Pousa A, Maurel J, Martín J, Martínez-Trufero J, Casado A, et al. Randomized phase II study comparing gemcitabine plus dacarbazine versus dacarbazine alone in patients with previously treated soft tissue sarcoma: a Spanish Group for Research on Sarcomas study. *J Clin Oncol.* 2011;29:2528–2533. doi:10.1200/JCO.2010.33.6107.
- Lee EM, Rha SY, Lee J, Park KH, Ahn J-H. Phase II study of weekly docetaxel and fixed dose rate gemcitabine in patients with previously treated advanced soft tissue and bone sarcoma. *Cancer Chemother Pharmacol.* 2012;69:635–642. doi:10.1007/s00280-011-1742-5.
- van der Graaf WTA, Blay J-Y, Chawla SP, Kim D-W, Bui-Nguyen B, Casali PG, et al. Pazopanib for metastatic soft-tissue sarcoma (PALETTE): a randomised, double-blind, placebo-controlled phase 3 trial. *Lancet.* 2012;379:1879–1886. doi:10.1016/S0140-6736(12)60651-5.
- Baruchel S, Pappo A, Krailo M, Baker KS, Wu B, Villaluna D, et al. A phase 2 trial of trabectedin in children with recurrent rhabdomyosarcoma, Ewing sarcoma and non-rhabdomyosarcoma soft tissue sarcomas: a report from the Children's Oncology Group. *Eur J Cancer.* 2012;48:579–585. doi:10.1016/j.ejca.2011.09.027.
- Ueda T, Kakunaga S, Ando M, Yonemori K, Sugiura H, Yamada K, et al. Phase I and pharmacokinetic study of trabectedin, a DNA minor groove binder, administered as a 24-h continuous infusion in Japanese patients with soft tissue sarcoma. *Invest New Drugs.* 2014;32:691–699. doi:10.1007/s10637-014-0094-5.
- Le Cesne A, Blay J-Y, Domont J, Tresch-Bruneel E, Chevreau C, Bertucci F, et al. Interruption versus continuation of trabectedin in patients with soft-tissue sarcoma (T-DIS): a randomised phase 2 trial. *Lancet Oncol.* 2015;16:312–319. doi:10.1016/S1470-2045(15)70031-8.

- [29] Kawai A, Araki N, Sugiura H, Ueda T, Yonemoto T, Takahashi M, et al. Trabectedin monotherapy after standard chemotherapy versus best supportive care in patients with advanced, translocation-related sarcoma: a randomised, open-label, phase 2 study. *Lancet Oncol.* 2015;16:406–416. doi:10.1016/S1470-2045(15)70098-7.
- [30] Kawai A, Araki N, Naito Y, Ozaki T, Sugiura H, Yazawa Y, et al. Phase 2 study of eribulin in patients with previously treated advanced or metastatic soft tissue sarcoma. *Jpn J Clin Oncol.* 2017;47:137–144. doi:10.1093/jjco/hyw175.
- [31] Schöffski P, Ray-Coquard IL, Cioffi A, Bui N Bin, Bauer S, Hartmann JT, et al. Activity of eribulin mesylate in patients with soft-tissue sarcoma: a phase 2 study in four independent histological subtypes. *Lancet Oncol.* 2011;12:1045–1052. doi:10.1016/S1470-2045(11)70230-3.
- [32] Natour RHA, Ashley SW, Tavakkolizadeh A. 797 outcomes of abdominal surgery in neutropenic patients. *Gastroenterol.* 2010;138:5-860. doi:10.1016/S0016-5085(10)63966-2
- [33] Dogar SA, Khan MAM. Implantable port devices in paediatric oncology patients: a clinical experience from a tertiary care hospital. *J Pak Med Assoc.* 2013;63:1248–1251.

● ● ● ● ●

**Authors:** Michiel van de Sande, Hiroyuki Tsuchiya, Diasuke Inoue, John Strony

### QUESTION 3: Should the serum white blood cell (WBC) count be taken into account prior to endoprosthetic reconstruction in patients who have undergone recent chemotherapy?

**RECOMMENDATION:** The association between chemotherapy and infection following endoprosthetic reconstruction remains controversial. However, in a multifactorial decision making process, there may be some benefit in accounting for the serum WBC count prior to endoprosthetic reconstruction.

**LEVEL OF EVIDENCE:** Limited

**DELEGATE VOTE:** Agree: 100%, Disagree: 0%, Abstain: 0% (Unanimous, Strongest Consensus)

#### RATIONALE

Infection continues to be one of the most serious complications after the reconstruction of an extremity using a tumor endoprosthesis. Past reports showed that the infection rate of a tumor endoprosthesis ranged from 4–36% [1–5]. The myelosuppressive properties of many chemotherapeutic drugs remain a theoretical risk for developing infection in these patients receiving a tumor endoprosthesis for an extremity tumor or metastatic lesions. However, this theoretical risk remains controversial. A handful of studies demonstrate a significant relationship between chemotherapy and periprosthetic infection in patients receiving an endoprosthetic device for an extremity tumor [3,6–9].

On the contrary, there are numerous studies that provide data supporting the idea that chemotherapy is not a significant risk factor for the development of periprosthetic joint infection (PJI) and surgical site infection (SSI) in these patients. Peel et al. [10] were able to demonstrate that chemotherapy, febrile neutropenia and bacteremia were not associated with the development of PJI. Jeys et al. [11] showed that there was no significant relationship between chemotherapy and the risk of infection. Biau et al. [12] reported that there was no significant difference in the rate of infection between patients who had received adjuvant treatment (including irradiation and chemotherapy) and those who had not received such treatment ( $p = 0.13$ ). Finally, Meijer et al. [13] found no association between chemoradiation and increased rates of endoprosthetic infection.

Despite the conflicting evidence surrounding chemotherapy and the risk of endoprosthetic infection, there may be some benefit in taking into account the patient's serum WBC count prior to endoprosthetic reconstruction. It is widely known that lymphocytes play an essential role in combatting invading pathogens and facilitating wound healing after surgery [14]. In addition, Gulack et al. [15] reported that preoperative leukopenia prior to emergent abdominal surgery was a predictor for significant postoperative morbidity and mortality. However, they were not able to demonstrate a significant difference in the incidence of deep wound infection in patients with leukopenia vs. patients with a normal WBC count preoperatively ( $p = 0.462$ ). These findings contrast with the work by Natour et al. [16], who noted that patients undergoing abdominal surgery with a preoperative absolute neutrophil count (ANC) less than 500

had significantly higher postoperative infection rates compared to patients who had a preoperative ANC between 500 and 1500. However, one must be cautious with the results from these studies, as they may not be generalizable to the particular patient cohort of focus.

Due to the fact that the literature doesn't show any significant differences between the infection rates between patients who are undergoing chemotherapy and those who are not receiving it, it makes sense to determine the WBC number as an additional diagnostic tool.

#### REFERENCES

- [1] Harges J, Gebert C, Schwappach A, Ahrens H, Streitburger A, Winkelmann W, et al. Characteristics and outcome of infections associated with tumor endoprostheses. *Arch Orthop Trauma Surg.* 2006;126:289–296. doi:10.1007/s00402-005-0009-1.
- [2] Zajonz D, Wuthe L, Tiepolt S, Brandmeier P, Prietzel T, von Salis-Soglio GF, et al. Diagnostic work-up strategy for periprosthetic joint infections after total hip and knee arthroplasty: a 12-year experience on 320 consecutive cases. *Patient Saf Surg.* 2015;9:20. doi:10.1186/s13037-015-0071-8.
- [3] Pala E, Trovarelli G, Calabrò T, Angelini A, Abati CN, Ruggieri P. Survival of modern knee tumor megaprotheses: failures, functional results, and a comparative statistical analysis. *Clin Orthop Relat Res.* 2015;473:891–899. doi:10.1007/s11999-014-3699-2.
- [4] Sevelde F, Schuh R, Hofstaetter JG, Schinhan M, Windhager R, Funovics PT. Total femur replacement after tumor resection: limb salvage usually achieved but complications and failures are common. *Clin Orthop Relat Res.* 2015;473:2079–2087. doi:10.1007/s11999-015-4282-1.
- [5] Haijie L, Dasen L, Tao J, Yi Y, Xiaodong T, Wei G. Implant survival and complication profiles of endoprostheses for treating tumor around the knee in adults: a systematic review of the literature over the past 30 years. *J Arthroplasty.* 2018;33:1275–1287.e3. doi:10.1016/j.arth.2017.10.051.
- [6] Gaur AH, Liu T, Knapp KM, Daw NC, Rao BN, Neel MD, et al. Infections in children and young adults with bone malignancies undergoing limb-sparing surgery. *Cancer.* 2005;104:602–610. doi:10.1002/cncr.21212.
- [7] Schinhan M, Tiefenboeck T, Funovics P, Sevelde F, Kotz R, Windhager R. Extendible prostheses for children after resection of primary malignant bone tumor: twenty-seven years of experience. *J Bone Joint Surg Am.* 2015;97:1585–1591. doi:10.2106/JBJS.N.00892.
- [8] Ji T, Guo W, Yang RL, Tang XD, Wang YF. Modular hemipelvic endoprosthesis reconstruction—experience in 100 patients with mid-term follow-up results. *Eur J Surg Oncol.* 2013;39:53–60. doi:10.1016/j.ejso.2012.10.002.
- [9] Guo W, Ji T, Yang R, Tang X, Yang Y. Endoprosthetic replacement for primary tumours around the knee: experience from Peking University. *J Bone Joint Surg Br.* 2008;90:1084–1089. doi:10.1302/0301-620X.90B8.20240.
- [10] Peel T, May D, Buising K, Thursky K, Slavin M, Choong P. Infective complications following tumour endoprosthesis surgery for bone and soft tissue tumours. *Eur J Surg Oncol.* 2014;40:1087–1094. doi:10.1016/j.ejso.2014.02.241.

- [11] Jeys LM, Grimer RJ, Carter SR, Tillman RM. Periprosthetic infection in patients treated for an orthopaedic oncological condition. *J Bone Joint Surg Am.* 2005;87:842–849. doi:10.2106/JBJS.C.01222.
- [12] Biau D, Faure F, Katsahian S, Jeanrot C, Tomeno B, Anract P. Survival of total knee replacement with a megaprosthesis after bone tumor resection. *J Bone Joint Surg Am.* 2006;88:1285–1293. doi:10.2106/JBJS.E.00553.
- [13] Meijer ST, Paulino Pereira NR, Nota SPFT, Ferrone ML, Schwab JH, Lozano Calderón SA. Factors associated with infection after reconstructive shoulder surgery for proximal humerus tumors. *J Shoulder Elbow Surg.* 2017;26:931–938. doi:10.1016/j.jse.2016.10.014.
- [14] Schäffer M, Barbul A. Lymphocyte function in wound healing and following injury. *Br J Surg.* 1998;85:444–460. doi:10.1046/j.1365-2168.1998.00734.x.
- [15] Gulack BC, Englum BR, Lo DD, Nussbaum DP, Keenan JE, Scarborough JE, et al. Leukopenia is associated with worse but not prohibitive outcomes following emergent abdominal surgery. *J Trauma Acute Care Surg.* 2015;79:437–443. doi:10.1097/TA.0000000000000757.
- [16] Natour RHA, Ashley SW, Tavakkolizadeh A. 797 outcomes of abdominal surgery in neutropenic patients. *Gastroenterology.* 2010;138:S-860. doi:10.1016/S0016-5085(10)63966-2.

Authors: Germán Luis Farfalli, Peter Choong, Sam Francis

## QUESTION 4: What should be the time delay between preoperative chemo/radiotherapy and a surgical tumor resection in order to minimize incidence of surgical site infection/periprosthetic joint infection (SSI/PJI)?

**RECOMMENDATION:** Unknown. There is no data that supports the best time delay between preoperative chemo/radiotherapy and a surgical tumor resection to minimize the incidence of SSI/PJI. There are multiple intrinsic factors of each patient that can determine the best time to implant an endoprosthesis after a neoadjuvant treatment. Although no significance was seen between preoperative radiotherapy and surgical timing on wound complications (WC), trends suggest rates are lower if surgery is performed between 3 and 6 weeks following radiotherapy.

**LEVEL OF EVIDENCE:** Consensus

**DELEGATE VOTE:** Agree: 100%, Disagree: 0%, Abstain: 0% (Unanimous, Strongest Consensus)

### RATIONALE

SSIs, PJIs and WCs can occur postoperatively with respect to musculoskeletal/orthopaedic related surgeries. The risk of these infections is more common when these surgeries are related to musculoskeletal tumor resections following established multimodal therapies of preoperative chemotherapy and/or radiotherapy [1,2]. SSIs are defined as infections occurring at the operative site that develop within 30 days of non-implant operation or 1 year in the case of implant (artificial material) based operations [3]. The incidence of SSIs following orthopaedic operations is 1–3% [4]. The incidence is expected to be much higher following surgery in malignant musculoskeletal tumors due to many patients' requiring preoperative/postoperative chemotherapy and/or radiotherapy. PJI after joint replacement surgery has been reported to occur in 1.55–2.5% of cases [5–7]. As with SSIs the incidence would be expected to be higher following tumor surgery. Wound complications rates have been shown to be higher in those receiving preoperative radiotherapy [6,8–10].

With respect to the timing of surgery after preoperative radiotherapy and/or chemotherapy, there is no established optimal timeframe for clinical practice. Decisions to date are made by clinician-team opinion. The effect of different timeframes on the development of SSI, PJI and WC rates in this group has not been extensively reviewed. We know that radiation impairs wound tissue repair through several mechanisms [11]. Ionizing radiation can damage fibroblasts leading to slow growth [12,13], dermal atrophy, necrosis and ultimately reduced wound strength [14–16]. As a result, in the initial period following radiotherapy, surgery is avoided and four weeks is thought to be required to allow for repopulation of normal tissues [17]. Acute systemic effects of chemotherapy are also well documented, including toxicity and immunosuppression. However, there is still no established timeframe with respect to when to surgically resect tumors post chemotherapy and this is guided by clinical assessment and clinician choice.

All seven included studies were retrospective case studies, four were single-center studies, while the other three were not specified. The total sample number of all seven studies combined was  $n = 1,585$ ;

sample sizes ranged from 18–798. Preoperative radiotherapy was used in five of the studies, preoperative chemotherapy in three.

SSI was statistically significant secondary to preoperative radiotherapy alone in three studies [19,21,23] and secondary to preoperative chemotherapy in two studies [21,22]. No statistical significance with respect to SSI and preoperative chemotherapy in one study [18]. The remaining two studies did not statistically assess SSI as an outcome measure [17,20]. Sugita et al., 2015, intended to study the effect of timing between radiotherapy and surgery on SSI; however, this was abandoned due to factors varying widely between cases [19].

None of the six included studies assess PJI as an outcome measure. There was no mention of PJIs being included in any other groups as a complication. Furthermore, no data on the effect of timing between radiotherapy and surgery on PJI was sourced.

One study showed statistical significance between neoadjuvant radiotherapy and postoperative infection,  $p = 0.008$ . This study did not classify specifically the type or location of these infections [23].

In terms of WC two of the studies assessed their association with preoperative treatment. Both studies looked at the effect of preoperative radiotherapy. Keam et al. ( $n = 165$ ) investigated the effect of preoperative radiotherapy on WCs and no statistical difference was evident with univariate analysis ( $p = 0.11$ ) [20]. This study also looked at the timing effect of  $< 30$  ( $n$  – not specified) days and  $\geq 30$  days ( $n$  – not specified) between radiotherapy and surgery on WC rates. There was no statistical significance between these two timeframes ( $p = 0.59$ ) [20]. Griffin et al., investigated the dichotomous effect of the time intervals of 3, 4, 5 and 6 between preoperative radiotherapy and surgery. The rate of wound complications was the primary outcome measure. When comparing  $\leq 3$  and  $> 3$  weeks, WC rates were 15/39 (38%) and 227/759 (30%) respectively,  $p = 0.3$ . Comparing  $\leq 4$  and  $> 4$  weeks, WC rates were 39/129 (30%) and 203/669 (30%) respectively,  $p = 1$ . Comparing  $\leq 5$  and 5 weeks, WC rates were 88/295 (30%) and 154/503 (31%) respectively,  $p = 0.8$ . Comparing  $\leq 6$  and 6 weeks, WC rates were 133/479 (28%) and 109/322 (34%) respectively,  $p = 0.08$ . At time points  $< 3$  and  $\geq 6$  weeks, it is evident that

TABLE 1. Data extraction from included studies

Author	Study Type	Neoadjuvant Treatment	Time Between Treatment and Surgery	n	Postoperative Outcome
Miwa et al., 2017 [18]	Single-centre Retrospective	Chemotherapy	Not specified	108	Deep SSI 16/108 significant with univariate analysis ( $p < 0.001$ ), not significant in multivariate analysis ( $p = 0.156$ )
Sugita et al., 2015 [19]	Non-specified Retrospective	Radiotherapy	Intention to analysis effect of timing *Abandoned	41	SSI 27/41 significant with univariate analysis ( $p = 0.03$ )
Griffin et al., 2015 [17]	Non-specified Retrospective	Radiotherapy	$\leq 3, > 3$ weeks $\leq 4, > 4$ weeks $\leq 5, > 5$ weeks $\leq 6, > 6$ weeks	39, 759 129, 669 295, 503 476, 322  Total n = 798	WC 15/39 (38%), 227/759 (30%), $p = 0.3$ WC 39/129 (30%), 203/669 (30%), $p = 1$ WC 88/295 (30%), 154/503 (31%), $p = 0.8$ WC 133/479 (28%), 109/322 (34%), $p = 0.08$  Overall WC 186/798 (23.3%) incidence SSI 56/798 (7%) incidence, *effect of time not studied
Keam et al., 2014 [20]	Single-center Retrospective	Radiotherapy	$> 30$ days $\leq 30$ days	165	No difference between effect of preoperative radiotherapy $> 30$ and $\leq 30$ days from surgery on wound complications ( $p = 0.59$ ) No significant effect on WC with univariate analysis ( $p = 0.11$ )
Gradl et al., 2014 [21]	Single-centrer Retrospective	Radiotherapy Chemotherapy	Immediate Not specified	262 137 Total n = 399	SSI 50/153, significant with bivariate analysis ( $p < 0.0001$ ) SSI 22/153, significant with bivariate analysis ( $p = 0.02$ )
Nagano et al., 2014 [22]	Single-center Retrospective	Chemotherapy	Not specified	18	SSI 6/18, significant with bivariate analysis ( $p = 0.03$ )
Behnke et al., 2014 [23]	Non-specified Retrospective	Radiotherapy	Not specified	56	Postoperative infection (Location/type not specified) in those with radiotherapy 14/56 (25%) when compared to those without 37/340 (11%), statistically significant, $p = 0.008$

there is a higher rate of WC (34-38%) when compared to 3-6 weeks (28-31%); however, statistically there is no difference between time points [17]. This trend, although not significant, may support the general avoidance of aiming for surgery too early or too late based on radiation induced local changes to tissue and skin. A large multi-center study may show more of an effect at these timeframes. This trend may be considered applicable to SSI/PJIs due to WC risk factors being theoretically close in nature to infection risk, particularly the local and systemic toxicities and effects of radiotherapy and chemotherapy respectively.

We identified seven relevant articles assessing the effect of preoperative treatment on SSI, PJI and WC with respect to musculoskeletal tumour resection. Results are highly variable between the studies and overall there is limited evidence of significance in results. SSI rates were significantly increased in 3/3 (100%) of studies that looked at preoperative radiotherapy and 2/3 (67%) of the studies that looked at preoperative chemotherapy. These are single center/non-specified studies; to further delineate results, larger multi-centre studies in the future are warranted. No effect on timing of preoperative treatment and surgery was observed with respect to SSI rates. Given that there is conflicting evidence between the effect of preoperative tumour treatment and SSI development, investigation

into the effect of timing becomes difficult. However, as some studies have established positive association and the near future possibility of larger multi-center study results coming to fruition, it will be now be imperative to also investigate and study the effects of surgical timing post radio/chemotherapy on rates of SSI. No studies assessed periprosthetic joint infection specifically as an outcome. This may be due to PJI presenting as a rare outcome secondary to surgical tumour resection. Also, these infections may be included in another complication section of such studies. None of the studies included in this review have mentioned this as an observed complication. Therefore, more investigation and study is needed with respect to understanding the role of preoperative tumour management and surgical timing on the rates PJI.

In summary, there is strong evidence supporting the association between preoperative radiotherapy/chemotherapy and postoperative SSIs. There is no data on the association of preoperative treatment with respect to PJI rates. One study showed no association between preoperative radiotherapy and WC. There were two studies showing no significant difference between surgical timing post radiotherapy/chemotherapy with respect to wound complications; however, there was a trend towards higher wound complications rates in  $\leq 3$  weeks and  $> 6$  weeks. More large-scale, well-designed

multi-center studies are required to more accurately assess the effect of timing between preoperative radiotherapy/chemotherapy and surgery on the rate of postoperative SSIs, PJI and WCs.

## REFERENCES

- [1] Grimer R, Judson I, Peake D, Seddon B. Guidelines for the management of soft tissue sarcomas. *Sarcoma*. 2010;2010:506182.
- [2] Grimer R, et al. UK guidelines for the management of bone sarcomas. *Sarcoma*. 2010;2010:317462.
- [3] Olsen MA, Chu-Ongsukul S, Brandt KE, Dietz JR, Mayfield J, Fraser VJ. Hospital-associated costs due to surgical site infection after breast surgery. *Arch Surg*. 2008;143(1):53–60.
- [4] Biondo S, Kreisler E, Fracalvieri D, Basany EE, Codina-Cazador A, Ortiz H. Risk factors for surgical site infection after elective resection for rectal cancer. A multivariate analysis on 2131 patients. *Colorectal Dis*. 2012;14(3):e95–e102.
- [5] Kurtz SM, Lau E, Watson H, et al. Economic burden of periprosthetic joint infection in the United States. *J Arthroplasty*. 2012;27:61–65.
- [6] O'Sullivan B, Davis AM, Turcotte R, Bell R, Catton C, Chabot P, Wunder J, Kandel R, Goddard K, Sadura A, Pater J, Zee B. Preoperative versus postoperative radiotherapy in soft-tissue sarcoma of the limbs: a randomised trial. *Lancet*. 2002;359(9325):2235–2241.
- [7] Lentino JR. Prosthetic joint infections: bane of orthopedists, challenge for infectious disease specialists. *Clin Infect Dis*. 2003;36(9):1157–1161.
- [8] Holt GE, Griffin AM, Pintilie M, Wunder JS, Catton C, O'Sullivan B, Bell RS. Fractures following radiotherapy and limb-salvage surgery for lower extremity soft-tissue sarcomas. A comparison of high-dose and low-dose radiotherapy. *J Bone Joint Surg Am*. 2005;87(2):315–319.
- [9] Davis AM, O'Sullivan B, Turcotte R, Bell R, Catton C, Chabot P, Wunder J, Hammond A, et al. Late radiation morbidity following randomization to preoperative versus postoperative radiotherapy in extremity soft tissue sarcoma. *Radiother Oncol*. 2005;75(1):48–53.
- [10] Cannon CP, Ballo MT, Zagars GK, Mirza AN, Lin PP, Lewis VO, Yasko AW, Benjamin RS, Pisters PW. Complications of combined modality treatment of primary lower extremity soft-tissue sarcomas. *Cancer*. 2006;107(10):2455–2461.
- [11] Itshayek E, Yamada J, Bilsky M, Schmidt M, Shaffrey C, Gerszten P, et al. Timing of surgery and radiotherapy in the management of metastatic spine disease: a systematic review. *Int J Oncol*. 2010;36:533–544.
- [12] Hill RP, Kaspler P, Griffin AM, O'Sullivan B, Catton C, Alasti H, et al. Studies of the in vivo radiosensitivity of human skin fibroblasts. *Radiother Oncol*. 2007;84:75–83.
- [13] Rudolph R, Vande Berg J, Schneider JA, Fisher JC, Poolman WL. Slowed growth of cultured fibroblasts from human radiation wounds. *Plast Reconstr Surg*. 1998;82:669–677.
- [14] Springfield, DS. Surgical wound healing. *Cancer Treat Res*. 1993;67:81–98.
- [15] Tibbs, MK. Wound healing following radiation therapy: a review. *Radiother Oncol*. 1997;42(2):99–106.
- [16] Denham JW, Hauer-Jensen M. The radiotherapeutic injury—a complex 'wound.' *Radiother Oncol*. 2002;63(2):129–145.
- [17] Griffin AM, Dickie CI, Catton CN, Chung PW, Ferguson PC, Wunder JS, O'Sullivan B. The influence of time interval between preoperative radiation and surgical resection on the development of wound healing complications in extremity soft tissue sarcoma. *Ann Surg Oncol*. 2015;22(9):2824–2830.
- [18] Miwa S, Shirai T, Yamamoto N, Hayashi K, Takeuchi A, Tada K, Kajino Y, Inatani H, Higuchi T, Abe K, Taniguchi Y, Tsuchiya H. Risk factors for postoperative deep infection in bone tumors. *PLoS One*. 2017;12(11).
- [19] Sugita S, Hozumi T, Yamakawa K, Goto T, Kondo T. Risk factors for surgical site infection after posterior fixation surgery and intraoperative radiotherapy for spinal metastases. *Eur Spine J*. 2016;25(4):1034–1038.
- [20] Keam J, Bilsky M, Laufer I, Shi W, Zhang Z, Tam M, Zatzky J, Lovelock DM, Yamada Y. No association between excessive wound complications and preoperative high-dose, hypofractionated, image-guided radiation therapy for spine metastasis. *J Neurosurg Spine*. 2014;20(4):411–420.
- [21] Gradl G, de Witte PB, Evans BT, Hornicek F, Raskin K, Ring D. Surgical site infection in orthopaedic oncology. *J Bone Joint Surg*. 2014;96(3):223–230.
- [22] Nagano S, Yokouchi M, Setoguchi T, Sasaki H, Shimada H, Kawamura I, Ishidou Y, Kamizono J, Yamamoto T, Kawamura H, Komiya S. Analysis of surgical site infection after musculoskeletal tumor surgery: risk assessment using a new scoring system. *Sarcoma*. 2014;2014:645496.
- [23] Behnke NK, Alamanda V, Song Y, Archer KR, Halpern JL, Schwartz HS, Holt GE. Does postoperative infection after soft tissue sarcoma resection affect oncologic outcomes? *J Surg Oncol*. 2014;109(5):415–420.

**Authors:** João Paulo Fonseca de Freitas, Diogo Moura, Arash Aalirezaie, John Abraham,\* John Strony,\* Keenan Sobol\*

## QUESTION 5: What strategies should be implemented to minimize the risk of surgical site infection/periprosthetic joint infection (SSI/PJI) in patients who have received chemotherapy or radiation therapy and are undergoing endoprosthetic reconstruction?

**RECOMMENDATION:** We believe patients who have received either chemotherapy or radiotherapy prior to endoprosthetic reconstruction should undergo extensive medical optimization. Consideration may also be given to the use of antimicrobial coated implants, extended (>24 h) and augmented postoperative antibiotic prophylaxis consisting of a first-generation cephalosporin and an aminoglycoside and/or vancomycin, as well as use of enhanced soft tissue reconstruction techniques. Surgery should also be expeditious in these patients minimizing dissection of soft tissues with gentle handling.

**LEVEL OF EVIDENCE:** Limited

**DELEGATE VOTE:** Agree: 100%, Disagree: 0%, Abstain: 0% (Unanimous, Strongest Consensus)

## RATIONALE

Patients with neoplasia undergoing endoprosthetic reconstruction are at an increased risk of SSI/PJI. The chemotherapy-induced immunosuppression, the poor soft-tissue conditions due to radiotherapy, the length and complexity of the tumor resection and megaprosthesis reconstruction and the difficulty of achieving soft tissue coverage are some of the reasons that explain the very high rate of infection in these patients compared to patients undergoing conventional arthroplasty [1–5].

As these patients are at high risk of SSI and/or PJI, any measure proven to be effective against infection should be implemented. Several organizations have proposed evidence-based guidelines for the prevention of surgical site infections. These strategies, together with additional measures, should be implemented in

these patients. We provide examples of some of the measures that may be used to minimize the risk of SSI/PJI in patients undergoing oncologic endoprosthetic joint reconstruction, particularly in patients who have received chemotherapy and/or irradiation treatment. These measures include:

- Preoperative measures [6–9]: Correction of hyperglycemia, treatment of anemia, treatment of malnutrition, smoking cessation, decolonization of *Staphylococcus aureus* (including methicillin-resistant *S. aureus* (MRSA)), skin cleansing with chlorhexidine or other antiseptic agents prior to surgery and numerous other preoperative measures that are discussed elsewhere in the consensus document should be considered.

- Intraoperative measures [6–9]: Administration of weight-based antibiotics, including coverage against MRSA if present, re-dosing of the prophylactic antibiotic for cases that last longer than two hours or have increased blood loss, minimizing blood loss by administration of tranexamic acid, minimizing operating room traffic, use of antibiotic-impregnated bone cement, wound irrigation with antiseptic agents such as sterile dilute betadine, careful and gentle soft tissue dissection and expeditious surgery are some of the proven strategies that may be implemented intraoperatively.
- Postoperative measures [6–9]: Wound management is a critical aspect of prevention of SSI/PJI in these patients. Consideration should be given to administration of less potent anticoagulation to minimize hematoma formation or reduce the chance for persistent wound drainage. The incision may be managed by application of negative pressure or occlusive dressing. Every effort should also be made to minimize blood loss and the need for allogeneic blood transfusion.

There are many other preventative measures that have been proposed or explored in oncologic patient population undergoing megaprosthesis reconstruction. In recent years the use of implants coated with antimicrobial agents such as silver and iodine has been explored. Silver-coated prostheses for limb reconstruction after tumor resection has been reported to have a favorable outcome and be effective in reduction of infection. Among the metals known to have antimicrobial activity, silver has attracted interest among many investigators due to its excellent level of antimicrobial activity and low toxicity. The silver coating can inhibit bacterial colonization of the prosthetic body and potentially prevent subsequent PJI [10–12]. A study involving patients with bone sarcoma over a five-year period demonstrated that the infection rate was substantially reduced from 17.6% in the uncoated titanium megaprosthesis (proximal femur,  $n = 33$ ; proximal tibia,  $n = 41$ ) to 5.9% in the silver-coated megaprosthesis group (proximal femur,  $n = 22$ ; proximal tibia,  $n = 29$ ). The titanium group data were retrospective and the data for the silver group were collected prospectively [13]. Another study evaluating the infection rate in 98 patients with sarcoma or giant-cell tumor in the proximal tibia demonstrated that infection at 16.7% in the group who underwent reconstruction using titanium megaprostheses ( $n = 42$ ) was significantly higher than the infection rate at 8.9% in the silver-coated megaprostheses group, resulting in five-year prosthesis survival rates of 90% in the silver-coated and 84% in the titanium only cohort. Although not reaching statistical significance, further work may suggest that silver-coated tumor prostheses may reduce the PJI rate in the high-risk oncological patients submitted to tumor resection and limb reconstruction.

Another study retrospectively investigated 68 oncology patients, 30 of whom received a titanium proximal femoral replacement and 38 patients who received a silver-coated proximal femur replacement. There was a lower rate of early infections (within the first 6 months) in the silver-coated group (2.6%) in comparison with 10% in the titanium group. However, the difference was not statistically significant. Regarding late-onset infections (later than 6 months), the difference between groups was not clear (5.3% in the silver group and 6.6% in the titanium group) [14]. The reports available on the use of silver-impregnated implants are all retrospective with their inherent limitations. The role of silver coating of megaprostheses in prevention of infection needs to be explored in a prospective manner.

Currently, there are no appropriate guidelines or recommendations in place for prophylactic antibiotics in patients with neoplasm undergoing endoprosthetic reconstruction. Although the beneficial role of perioperative antibiotic prophylaxis is proven, it is not known whether continuation of antibiotics beyond the traditional 24 hours is beneficial. Further, there is no consensus among the

experts on the type of antibiotic prophylaxis that may be needed in tumor surgery patients with great variation between centers. Although most surgeons provide gram-positive coverage, others also provide gram-negative coverage. In addition, the length of administration of postoperative antibiotics has varied vastly [2,15]. A cross-sectional international survey of practicing orthopaedic oncology surgeons found that 73% (95% confidence interval (CI) 61, 82%) of respondents prescribe a first-generation cephalosporin, 25% favor additional coverage with an aminoglycoside (gentamycin) and/or vancomycin or teicoplanin. Of those who prescribe a cephalosporin, 33% prescribe a dosage of one gram for all patients and the remainder prescribe up to 2 grams based on the body weight. One in three surgeons (95% CI: 25, 48%) believe antibiotics could be discontinued after 24 hours, but 40% of surgeons (95% CI: 30, 53%) continue antibiotics until the suction drain is removed.

In higher-risk cases of tumor patients who have received chemotherapy and/or irradiation, no guidelines exist to direct antibiotic management. It is a common practice to continue the antibiotics beyond 24 hours in these patients. There is no prospective study that has examined the efficacy of different antibiotic regimens in preventing infection in long-bone prosthetic reconstruction [15].

Studies comparing single-dose prophylaxis and multiple-dose prophylaxis in a general surgery setting have not shown any benefit to extended course of antibiotics [16]. A systematic review involving 48 studies on a total of 4,838 patients (level IV retrospective studies) suggests that long-term (greater than 24 hours) postoperative antibiotic prophylaxis is more effective at minimizing infection risk in patients with lower extremity long-bone tumors that require surgery and endoprosthetic reconstruction. However, the data should be interpreted with caution owing to the retrospective nature of the included studies. The overall pooled weighted infection rate for lower-extremity limb salvage surgery with endoprosthetic reconstruction was approximately 10% (95% CI: 8%–11%), with the most common causative organism reported to be gram-positive bacteria in the majority of cases. Twenty studies reported postoperative antibiotic regimens, so they were further subdivided into short-term regimens (0 to 24 hours of postoperative antibiotics) and long-term regimens (greater than 24 hours of postoperative antibiotics) and compared. The pooled infection rate following short-term postoperative antibiotic prophylaxis was 13% (95% CI: 9% to 17%;  $p < 0.001$ ), which is slightly higher than the overall pooled infection rate. The pooled infection rate for the long-term postoperative antibiotic prophylaxis was 8% (95% CI: 6% to 12%;  $p < 0.05$ ), which is slightly lower than the overall pooled infection rate. This difference in the pooled infection rates following short-term and long-term postoperative antibiotics was statistically significant ( $p < 0.05$ ) [2].

There is no dispute to suggest that tumor patients undergoing endoprosthetic reconstruction are at higher risk of infection than those undergoing conventional joint arthroplasty. The risk of infection is further increased in patients who have received chemotherapy or irradiation treatment. Thus, any measure to minimize the risk of infection in this patient population needs to be implemented. We have proposed some preventative measures above but there is a desperate need for further studies to examine further measures.

\* These authors answered a different question that was very similar to this one. The consensus voted to remove that question from publication due to its similarity with the current question. Though the question was removed, we want to acknowledge these authors for their work.

## REFERENCES

- [1] Jeys LM, Luscombe JS, Grimer RJ, Abudu A, Tillman RM, Carter SR. The risks and benefits of radiotherapy with massive endoprosthetic replacement. *J Bone Joint Surg Br.* 2007;89:1352–1355. doi:10.1302/0301-620X.89B10.19233.



- [2] Racano A, Pazonis T, Farrokhyar F, Dehesi B, Ghert M. High infection rate outcomes in long-bone tumor surgery with endoprosthetic reconstruction in adults: a systematic review. *Clin Orthop Relat Res*. 2013;471:2017–2027. doi:10.1007/s11999-013-2842-9.
- [3] Schmidt-Braekling T, Streitburger A, Gosheger G, Boettner F, Nottrott M, Ahrens H, et al. Silver-coated megaprotheses: review of the literature. *Eur J Orthop Surg Traumatol*. 2017;27:483–489. doi:10.1007/s00590-017-1933-9.
- [4] Jeys LM, Grimer RJ, Carter SR, Tillman RM. Periprosthetic infection in patients treated for an orthopaedic oncological condition. *J Bone Joint Surg Am*. 2005;87:842–849. doi:10.2106/JBJS.C.01222.
- [5] Payne WG, Naidu DK, Wheeler CK, Barkoe D, Mentis M, Salas RE, et al. Wound healing in patients with cancer. *Eplasty*. 2008;8:e9.
- [6] Parvizi J, Shohat N, Gehrke T. Prevention of periprosthetic joint infection: new guidelines. *Bone Joint J*. 2017;99-B:3–10. doi:10.1302/0301-620X.99B4.BJ-2016-1212.R1.
- [7] Parvizi J, Gehrke T, Chen AE. Proceedings of the International Consensus on Periprosthetic Joint Infection. *Bone Joint J*. 2013;95-B:1450–1452. doi:10.1302/0301-620X.95B11.33135.
- [8] WHO | Global guidelines on the prevention of surgical site infection. WHO n.d. <http://www.who.int/gpsc/ssi-guidelines/en/> (accessed July 12, 2018).
- [9] Anderson DJ, Podgorny K, Berrios-Torres SI, Bratzler DW, Dellinger EP, Greene L, et al. Strategies to prevent surgical site infections in acute care hospitals: 2014 update. *Infect Control Hosp Epidemiol*. 2014;35 Suppl 2:S66–S88.
- [10] Harges J, Henrichs MP, Hauschild G, Nottrott M, Guder W, Streitburger A. Silver-coated megaprosthesis of the proximal tibia in patients with sarcoma. *J Arthroplasty*. 2017;32:2208–2213. doi:10.1016/j.arth.2017.02.054.
- [11] Gosheger G, Harges J, Ahrens H, Streitburger A, Buerger H, Erren M, et al. Silver-coated megaendoprostheses in a rabbit model—an analysis of the infection rate and toxicological side effects. *Biomaterials*. 2004;25:5547–5556. doi:10.1016/j.biomaterials.2004.01.008.
- [12] Harges J, Ahrens H, Gebert C, Streitburger A, Buerger H, Erren M, et al. Lack of toxicological side-effects in silver-coated megaprotheses in humans. *Biomaterials*. 2007;28:2869–2875. doi:10.1016/j.biomaterials.2007.02.033.
- [13] Harges J, von Eiff C, Streitburger A, Balke M, Budny T, Henrichs MP, et al. Reduction of periprosthetic infection with silver-coated megaprotheses in patients with bone sarcoma. *J Surg Oncol*. 2010;101:389–395. doi:10.1002/jso.21498.
- [14] Donati F, Di Giacomo G, D'Adamo S, Ziranu A, Careri S, Rosa M, et al. Silver-coated hip megaprosthesis in oncological limb salvage surgery. *BioMed Res Int*. 2016;2016:9079041. doi:10.1155/2016/9079041.
- [15] Hasan K, Racano A, Dehesi B, Farrokhyar F, Wunder J, Ferguson P, et al. Prophylactic antibiotic regimens in tumor surgery (PARITY) survey. *BMC Musculoskelet Disord*. 2012;13:91. doi:10.1186/1471-2474-13-91.
- [16] McDonald M, Grabsch E, Marshall C, Forbes A. Single- versus multiple-dose antimicrobial prophylaxis for major surgery: a systematic review. *Aust N Z J Surg*. 1998;68:388–396.

### 1.3. PREVENTION: RESEARCH CAVEATS

Authors: Rodolfo Capanna, Ivan Boháček, Lorenzo Andreani

**QUESTION 1:** What are the significant risk factors for surgical site infection/periprosthetic joint infection (SSI/PJI) of an oncologic endoprosthesis following resection of a malignant bone tumor?

**RECOMMENDATION:** Patient-related risk factors for SSI/PJI of an oncologic endoprosthesis include increased patients' body mass index, overall presence of comorbidities, coexistence of superficial SSI or skin necrosis and lower preoperative hemoglobin or albumin levels. Disease-related risk factors for SSI/PJI of an oncologic endoprosthesis include lesion localization in proximal tibia, pelvis and lesion extending to pelvis from proximal femur. In addition, procedure related risk factors for SSI/PJI include preoperative hospitalization longer than 48 hours, resection of greater than 37% of the proximal tibia, resection of 3 or 4 heads of the quadriceps muscle in distal femoral lesions compared to 1 or 2 heads, increasing surgical time (longer than 2.5 h), use of cemented oncologic endoprosthesis, need for postoperative admission to the intensive care unit, increased postoperative blood transfusion requirement (2 or more units of allogeneic packed cells), presence of postoperative hematoma and the need for additional surgical procedures after the megaprosthesis implantation.

**LEVEL OF EVIDENCE:** Moderate

**DELEGATE VOTE:** Agree: 100%, Disagree: 0%, Abstain: 0% (Unanimous, Strongest Consensus)

#### RATIONALE

Periprosthetic joint infection represents one of the most challenging complications following any joint replacement and may result in devastating consequences. According to a recent systematic review, the mean rate of periprosthetic infection of a megaprosthesis (PMI) is 10% after primary procedure and 43% after revision procedures of infected cases [1,2].

Despite the lack of multiple randomized clinical trials, several retrospective studies (Level IV) showed significant risk factors for SSI/PJI of an oncologic endoprosthesis following resection of a malignant bone tumor. In a systematic review of the literature, De Gori et al. examined risk factors for PMI [3]. A total of 8 articles, all retrospective, including 2,136 patients, met the inclusion criteria and were analyzed [4–11]. The overall PMI rate was 14.2%. Patient-related factors associated with a significantly higher risk of PMI included increasing patients' body mass index and overall presence of comorbidities (but not the American Society of Anesthesiologists (ASA) score or diabetes mellitus specifically) and coexistence of superficial surgical site infection or skin necrosis. Disease-related factors associated with increased risk for PMI included lesion local-

ization in proximal tibia, pelvis and lesion extending to pelvis from proximal femur. In contrast, lesions localized in the distal femur appear to be protective for PMI occurrence. There was no association between primary tumor histological features or metastatic spread and PMI. In addition, there was no significant effect of chemotherapy and radiotherapy for the development of PMI, which is in contrast to several studies [12–15] which report increased incidence of infection rate associated with chemotherapy and radiotherapy. Controversy also still exists regarding whether primary or metastatic lesions have higher risk for PMI [3,12]. In this systematic review, procedure-related factors associated with higher risk of PMI included preoperative hospitalization longer than 48 hours, resection of greater than 37% of the proximal tibia, resection of 3 or 4 heads of the quadriceps muscle in distal femoral lesions compared to 1 or 2 heads, increasing surgical time (longer than 2.5 h), need for postoperative admission to the intensive care unit, increased postoperative blood transfusion requirement (2 or more units of allogeneic packed cells), presence of postoperative hematoma and the need for additional surgical procedures after the megaprosthesis

implantation. According to this systematic review, features of perioperative antibiotic prophylaxis do not affect PJI rates, i.e., choice of antibiotic used, dosing, number of antibiotics used postoperatively or length of prophylaxis, which is in contrast to previous systematic review conclusions [1]. In addition, width of resection margins, bone resection length and extracapsular resection of knee tumors were not associated with increased rates of PMI. There was no difference in PMI rates according to prosthesis type or hinge movement, but two studies have shown that cemented megaprotheses have led to a higher PMI rate compared to uncemented ones, thus contradicting information regarding conventional arthroplasties. Routine use of gastrocnemius flap for anterior reconstruction and megaprosthesis coverage following proximal tibia resection has led to a reduced rate of PMI. Data of this systematic review supports the idea that soft tissue condition merely influences the PMI rate [16].

According to a most recent Level III retrospective cohort study on 150 patients, reported by Meijer et al., factors associated with infection after reconstructive shoulder surgery for proximal humerus tumors were lower preoperative hemoglobin or albumin levels and these patients should undergo optimization before surgery [17]. In addition, a lower WBC count and positive resection margins were associated with superficial infection and younger age with deep infection [17]. Furthermore, the location of the endoprosthesis may also influence the infection risk as the lower extremities have been demonstrated to have a greater risk of infection than the upper extremities [15].

## REFERENCES

- [1] Racano A, Pazonis T, Farrokhyar F, Deheshi B, Ghert M. High infection rate outcomes in long-bone tumor surgery with endoprosthetic reconstruction in adults: a systematic review. *Clin Orthop Relat Res.* 2013;471:2017-2027. doi:10.1007/s11999-013-2842-9.
- [2] Capanna R, Morris HG, Campanacci D, Del Ben M, Campanacci M. Modular uncemented prosthetic reconstruction after resection of tumours of the distal femur. *J Bone Joint Surg Br* 1994;76:178-186.
- [3] De Gori M, Gasparini G, Capanna R. Risk factors for perimegaprosthesis infections after tumor resection. *Orthopedics.* 2017;40:e11-e16. doi:10.3928/01477447-20161128-01.
- [4] Dhanoa A, Ajit Singh V, Elbahri H. deep infections after endoprosthetic replacement operations in orthopedic oncology patients. *Surg Infect.* 2015;16:323-332. doi:10.1089/sur.2014.049.
- [5] Mavrogenis AF, Pala E, Angelini A, Calabro T, Romagnoli C, Romantini M, et al. Infected prostheses after lower-extremity bone tumor resection: clinical outcomes of 100 patients. *Surg Infect.* 2015;16:267-275. doi:10.1089/sur.2014.085.
- [6] Capanna R, Scoccianti G, Frenos F, Vilardi A, Beltrami G, Campanacci DA. What was the survival of megaprotheses in lower limb reconstructions after tumor resections? *Clin Orthop Relat Res.* 2015;473:820-830. doi:10.1007/s11999-014-3736-1.
- [7] Peel T, May D, Buising K, Thursky K, Slavin M, Choong P. Infective complications following tumour endoprosthesis surgery for bone and soft tissue tumours. *Eur J Surg Oncol.* 2014;40:1087-1094. doi:10.1016/j.ejso.2014.02.241.
- [8] Cho WH, Song WS, Jeon D-G, Kong C-B, Kim JI, Lee S-Y. Cause of infection in proximal tibial endoprosthetic reconstructions. *Arch Orthop Trauma Surg.* 2012;132:163-169. doi:10.1007/s00402-011-1405-3.
- [9] Funovics PT, Hipfl C, Hofstaetter JG, Puchner S, Kotz RI, Dominkus M. Management of septic complications following modular endoprosthetic reconstruction of the proximal femur. *Int Orthop.* 2011;35:1437-1444. doi:10.1007/s00264-010-1054-0.
- [10] Morii T, Yabe H, Morioka H, Beppu Y, Chuman H, Kawai A, et al. Postoperative deep infection in tumor endoprosthesis reconstruction around the knee. *J Orthop Sci.* 2010;15:331-339. doi:10.1007/s00776-010-1467-z.
- [11] Myers GJC, Abudu AT, Carter SR, Tillman RM, Grimer RJ. The long-term results of endoprosthetic replacement of the proximal tibia for bone tumours. *J Bone Joint Surg Br.* 2007;89:1632-1637. doi:10.1302/0301-620X.89B12.19481.
- [12] Allison D, Huang E, Ahlmann E, Carney S, Wang L, Menendez L. Peri-prosthetic infection in the orthopedic tumor patient. *Reconstr Rev.* 2014;4.
- [13] Jeys LM, Luscombe JS, Grimer RJ, Abudu A, Tillman RM, Carter SR. The risks and benefits of radiotherapy with massive endoprosthetic replacement. *J Bone Joint Surg Br.* 2007;89:1352-1355. doi:10.1302/0301-620X.89B10.19233.
- [14] McDonald DJ, Capanna R, Gherlinzoni F, Bacci G, Ferruzzi A, Casadei R, et al. Influence of chemotherapy on perioperative complications in limb salvage surgery for bone tumors. *Cancer.* 1990;65:1509-1516.
- [15] Jeys LM, Grimer RJ, Carter SR, Tillman RM. Periprosthetic infection in patients treated for an orthopaedic oncological condition. *J Bone Joint Surg Am.* 2005;87:842-849. doi:10.2106/JBJS.C.01222.
- [16] Harges J, Gebert C, Schwappach A, Ahrens H, Streitburger A, Winkelmann W, et al. Characteristics and outcome of infections associated with tumor endoprostheses. *Arch Orthop Trauma Surg.* 2006;126:289-296. doi:10.1007/s00402-005-0009-1.
- [17] Meijer ST, Paulino Pereira NR, Nota SPFT, Ferrone ML, Schwab JH, Lozano Calderón SA. Factors associated with infection after reconstructive shoulder surgery for proximal humerus tumors. *J Shoulder Elbow Surg.* 2017;26:931-938. doi:10.1016/j.jse.2016.10.014.



**Authors:** Roberto Velez, Michelle Ghert, James Yan, Matias Vicente

## QUESTION 2: What metrics should be used to determine the optimal timing of reimplantation for patients with a resected oncologic endoprosthesis?

**RECOMMENDATION:** Prior to reimplantation of an oncologic endoprosthesis after a previous resection, surgeons must ensure that the infection has been eradicated from the surgical bed. This would be determined via a sterile aspirate from the joint cavity following the antibiotic treatment.

**LEVEL OF EVIDENCE:** Moderate

**DELEGATE VOTE:** Agree: 100%, Disagree: 0%, Abstain: 0% (Unanimous, Strongest Consensus)

## RATIONALE

Periprosthetic infection following oncologic endoprosthetic limb salvage surgery is a well-recognized and devastating complication [1]. Surgeons who treat oncologic patients with endoprostheses need to have a low tolerance to suspected periprosthetic infection. Oncology patients are at greater risk of infection than general arthroplasty patients, up to 15% of oncological endoprosthetic reconstructions compared to 1-2% within the general population [2,3]. Early diagnosis and treatment are key to outcome. Surgical treatment options include amputation, irrigation and debridement, excision arthroplasty, and one- and two-stage revision, along with targeted

antibiotic therapy. Two-stage revision involves initial irrigation, debridement, removal of the endoprosthesis with implantation of a cement spacer and later reimplantation of the device. Despite the established acknowledgement that the two-stage revision is the gold standard for surgical treatment [4], there is a limited amount of information on the clinical parameters that should be used to optimize the reimplantation of an endoprosthesis following initial staged debridement and resection.

A search of the literature found nine retrospective studies, six retrospective cohort studies and three retrospective case studies

**TABLE 1. Endoprosthetic infection two-stage revision study data**

Study Name	Study Type	Total Number of Patients	Number of Patients Who Developed Infections	Infected Patients Who Underwent Two-stage Revision	Patients With Infections Controlled Successfully (%)
Jeys et al., 2005	Retrospective cohort study	1264	136	58	42 (72%)
Funovics et al., 2011	Retrospective cohort study	170	12	2	2 (100%)
Hardes et al., 2006	Retrospective case study	30	30	15	12 (80%)
Donati et al., 1998	Retrospective cohort study	35	20	19	14 (74%)
Rao et al., 2006	Retrospective cohort study	9	9	9	8 (89%)
Manoso et al., 2006	Retrospective case series	11	11	11	10 (91%)
Grimer et al., 2002	Retrospective case series	34	34	34	25 (74%)

[5–13]. Seven of these studies required clearance of residual infection as determined by a sterile aspirate sample from the periprosthetic space before the revision endoprosthesis could be reinserted [5–11]. These studies showed the success rate of preventing reinfection ranged between 72–100% if reimplantation was conducted using this metric.

The results of four studies following one-stage revision to control infection varied. This approach was performed when the operating surgeons deemed the infection was early in its course or low grade. Funovics et al. reported success rate of 62.5% (5 out of 8 patients) [6]. Jeys et al. found 47% (15 out of 32) of one-stage revisions eradicated the infection [5]. Hardes et al. only found success in 1 out of 3 patients (33%) treated with this technique [11]. Holzer et al. reported a success rate comparable to those reported by two-stage revisions at 78% (14 out of 18 patients cleared their infections) [12]. The results of these studies show that the efficacy of one-stage revisions in treating infected oncological endoprostheses is inferior to that of a two-stage approach following negative aspirates. However, the low sample numbers make it difficult to draw a definitive conclusion.

Finally, four of the studies also reported on the importance of adequate soft tissue coverage prior to reimplantation [9–11,13]. This was used as a subjective clinical parameter. Three studies noted that the decision to proceed to the second stage was delayed until adequate soft tissue coverage and wound healing was seen [10,11,13]. Rao et al. noted the influence of different types of soft tissue flaps on infection control in two-stage revisions [9].

Despite the lack of higher quality literature, there has been consistent support by several retrospective studies for using sterile periprosthetic cavity aspirates as a clinical metric to indicate optimal timing for oncological endoprosthesis reimplantation. Other subjective parameters, such as soft tissue coverage and stage of infection, were also recorded. While clearer parameters exist in revision cases for general arthroplasty, more robust evidence, including larger sample sizes and randomized clinical trials, are desired for

oncological endoprosthesis. Thus, only a moderate strength recommendation can be provided.

## REFERENCES

- [1] Rossi B, Zoccali C, Toma L, Ferraresi V, Biagini R. Surgical site infections in treatment of musculoskeletal tumors: experience from a single oncologic orthopedic institution. ResearchGate 2016. [https://www.researchgate.net/publication/304744960\\_Surgical\\_Site\\_Infections\\_in\\_Treatment\\_of\\_Musculoskeletal\\_Tumors\\_Experience\\_from\\_a\\_Single\\_Oncologic\\_Orthopedic\\_Institution](https://www.researchgate.net/publication/304744960_Surgical_Site_Infections_in_Treatment_of_Musculoskeletal_Tumors_Experience_from_a_Single_Oncologic_Orthopedic_Institution) (accessed July 18, 2018).
- [2] Allison D, Huang E, Ahlmann E, Carney S, Wang L, Menendez L. Peri-prosthetic infection in the orthopedic tumor patient. *Reconstr Rev*. 2014;4.
- [3] Kapadia BH, Berg RA, Daley JA, Fritz J, Bhawe A, Mont MA. Periprosthetic joint infection. *Lancet*. 2016;387:386–394. doi:10.1016/S0140-6736(14)61798-0.
- [4] Kapoor SK, Thiyam R. Management of infection following reconstruction in bone tumors. *J Clin Orthop Trauma*. 2015;6:244–251. doi:10.1016/j.jcot.2015.04.005.
- [5] Jeys LM, Grimer RJ, Carter SR, Tillman RM. Periprosthetic infection in patients treated for an orthopaedic oncological condition. *J Bone Joint Surg Am*. 2005;87:842–849. doi:10.2106/JBJS.C.01222.
- [6] Funovics PT, Hipfl C, Hofstaetter JG, Puchner S, Kotz RI, Dominkus M. Management of septic complications following modular endoprosthetic reconstruction of the proximal femur. *Int Orthop*. 2011;35:1437–1444. doi:10.1007/s00264-010-1054-0.
- [7] Donati D, Biscaglia R. The use of antibiotic-impregnated cement in infected reconstructions after resection for bone tumours. *J Bone Joint Surg Br*. 1998;80:1045–1050.
- [8] Manoso MW, Boland PJ, Healey JH, Cordeiro PG. Limb salvage of infected knee reconstructions for cancer with staged revision and free tissue transfer. *Ann Plast Surg*. 2006;56:532–535; discussion 535. doi:10.1097/01.sap.0000203990.08414.ad.
- [9] Rao K, Lahiri A, Peart FC. Role of staged endoprosthetic revision with flap cover for limb salvage in endoprosthetic failure. *Int Orthop*. 2006;30:473–477. doi:10.1007/s00264-006-0103-1.
- [10] Grimer RJ, Belthur M, Chandrasekar C, Carter SR, Tillman RM. Two-stage revision for infected endoprostheses used in tumor surgery. *Clin Orthop Relat Res*. 2002;193–203.
- [11] Hardes J, Gebert C, Schwappach A, Ahrens H, Streiburger A, Winkelmann W, et al. Characteristics and outcome of infections associated with tumor endoprostheses. *Arch Orthop Trauma Surg*. 2006;126:289–296. doi:10.1007/s00402-005-0009-1.
- [12] Holzer G, Windhager R, Kotz R. One-stage revision surgery for infected megaprostheses. *J Bone Joint Surg Br*. 1997;79:31–35.
- [13] Morii T, Morioka H, Ueda T, Araki N, Hashimoto N, Kawai A, et al. Deep infection in tumor endoprosthesis around the knee: a multi-institutional study by the Japanese Musculoskeletal Oncology Group. *BMC Musculoskelet Disord*. 2013;14:51. doi:10.1186/1471-2474-14-51.



## 1.4. PREVENTION: SURGICAL TECHNIQUE

**Authors:** Aare Märtson, Oscar Ares, Jacek Markuszewski, Ignacio Moya, Andrea Sallent

**QUESTION 1:** Is there an increased risk for subsequent surgical site infection/periprosthetic joint infection (SSI/PJI) when a drainage tube is used in musculoskeletal tumor surgery?

**RECOMMENDATION:** Surgical drains should be used selectively in patients undergoing musculoskeletal tumor surgery. If used, they should be continuously monitored and removed immediately once output has decreased adequately per clinical judgment. There is a potential, yet unproven, link between the use of surgical drains and increased risk of SSI/PJI following orthopaedic procedures involving the use of prostheses.

**LEVEL OF EVIDENCE:** Limited

**DELEGATE VOTE:** Agree: 100%, Disagree: 0%, Abstain: 0% (Unanimous, Strongest Consensus)

### RATIONALE

Known risk factors for infection after musculoskeletal tumor surgery include malignancy of the primary tumor, duration of operative time, history of previous surgeries, use of chemotherapy and/or radiotherapy, tumor affectation of the skin and skin necrosis [1]. An additional area of concern in which more information is desired involves the use of surgical drains postoperatively in orthopaedic surgery patients undergoing oncologic procedures. Due to the extensive tissue dissection and exposure needed for musculoskeletal tumor removal, it is not uncommon for drains to be used postoperatively [2–6]. A consensus regarding the risk of SSI/PJI in musculoskeletal tumor surgery due to surgical drain use/duration of the drain remaining in situ has yet to be established.

The relationship between the use of surgical drains and the onset of infection has been examined in previous works. In a review of 723 musculoskeletal tumor surgeries among patients where drains were kept in 2–3 days (non-pelvic tumors) and 5 days (pelvic tumors), Rossi et al. found an overall infection rate was 8.7% [5]. Literature has a tendency to signal drainage tubes increase infection risks in musculoskeletal tumor surgeries. This may be due to the fact that they connect the endoprosthesis or the site affected by the tumor with the outside flora, thus making colonization by microorganisms, such as *Staphylococcus aureus*, more likely. Rates of SSI, with skin flora bacteria, such as *S. aureus*, have been increasing over the last decade. The exact reason for this increase is unknown but could relate to the use of surgical drainage in patients undergoing musculoskeletal tumor surgery [6].

To date, there is no consensus on how long surgical drains should remain in place after surgery and whether or not they contribute to the risk of orthopaedic oncology patients developing SSI/PJI. Per the World Health Organization (WHO), low-quality evidence shows the early removal of wound drains has neither benefit nor harm in reducing the SSI rate when compared to its late removal among any patient undergoing a surgical procedure [7]. Lerman et al. conducted a retrospective review of 165 patients with musculoskeletal tumor surgeries [3]. In their cohort, 10.3% of all patients had 2 surgical drains remain intact 24 hours postoperatively. However, surgical drain usage was not accounted for in the study's univariate analysis. In Shehadeh et al.'s retrospective review of 232 patients, overall infection rates in the group were similar at 11.36% [4]. In their protocol, drain tubes were removed when their debit was less than 30cc since

the last shift. As with Lerman et al.'s study, commentary cannot be made regarding the influence drain usage had on the rate presented, because it was not accounted for in the study's statistical analysis.

Further insight can be obtained by a meta-review done by the WHO. Thirty-four systematic reviews investigating the effect of drains compared to no wound drainage in terms of the related infection risk in patients undergoing various surgical procedures were reviewed [7]. Review of the meta-analyses showed a tendency towards a beneficial effect of not using a wound drain with regard to a reduced risk of wound infections with no statistical significance. One of the few proven benefits of drains is a reduced need for a change of the dressing and increased comfort (observed among patients receiving total hip arthroplasty) [8,9]. Taking these factors into consideration and current status of the literature, decision making is to be made at the discretion of the clinician at this time. Further investigation into surgical drain use and its influence on SSI/PJI in musculoskeletal tumor surgery is warranted.

### REFERENCES

- [1] Morii T, Yabe H, Morioka H, Beppu Y, Chuman H, Kawai A, et al. Postoperative deep infection in tumor endoprosthesis reconstruction around the knee. *J Orthop Sci.* 2010;15:331–339. doi:10.1007/s00776-010-1467-z.
- [2] Holzer G, Windhager R, Kotz R. One-stage revision surgery for infected megaprotheses. *J Bone Joint Surg Br.* 1997;79:31–35.
- [3] Lerman DM, Blank AT, Billig JJ, Karia R, Rapp TB. Identification of risk factors for acute surgical site infections in musculoskeletal tumor patients using CDC/NHSN criteria. *Bull Hosp Jt Dis.* 2013 2015;73:233–238.
- [4] Shehadeh A, Noveau J, Malawer M, Henshaw R. Late complications and survival of endoprosthetic reconstruction after resection of bone tumors. *Clin Orthop Relat Res.* 2010;468:2885–2895. doi:10.1007/s11999-010-1454-x.
- [5] Rossi B, Zoccali C, Toma L, Ferraresi V, Biagini R. Surgical site infections in treatment of musculoskeletal tumors: experience from a single oncologic orthopedic institution. *ResearchGate* 2016. [https://www.researchgate.net/publication/304744960\\_Surgical\\_Site\\_Infections\\_in\\_Treatment\\_of\\_Musculoskeletal\\_Tumors\\_Experience\\_from\\_a\\_Single\\_Oncologic\\_Orthopedic\\_Institution](https://www.researchgate.net/publication/304744960_Surgical_Site_Infections_in_Treatment_of_Musculoskeletal_Tumors_Experience_from_a_Single_Oncologic_Orthopedic_Institution) (accessed July 18, 2018).
- [6] Morii T, Mochizuki K, Tajima T, Ichimura S, Satomi K. Surgical site infection in malignant soft tissue tumors. *J Orthop Sci.* 2012;17:51–57. doi:10.1007/s00776-011-0179-3.
- [7] Leaper DJ, Edmiston CE. World Health Organization: global guidelines for the prevention of surgical site infection. *J Hosp Infect.* 2017;95:135–136. doi:10.1016/j.jhin.2016.12.016.
- [8] Parker MJ, Roberts CP, Hay D. Closed suction drainage for hip and knee arthroplasty. A meta-analysis. *J Bone Joint Surg Am.* 2004;86-A:1146–1152.
- [9] Strahovnik A, Fokter SK, Kotnik M. Comparison of drainage techniques on prolonged serous drainage after total hip arthroplasty. *J Arthroplasty.* 2010;25:244–248. doi:10.1016/j.arth.2008.08.014.



**Authors:** Christina Gutowski, Michelle Ghert, Anthony Bozzo, Marc Levine

## **QUESTION 2:** When should a surgical drain be removed to minimize the risk of subsequent surgical site infection/periprosthetic joint infection (SSI/PJI) in patients who have received endoprosthetic reconstruction (EPR) following resection of a musculoskeletal tumor?

**RECOMMENDATION:** Based on the available literature, we recommend drains be removed within 24 hours of surgery.

**LEVEL OF EVIDENCE:** Limited

**DELEGATE VOTE:** Agree: 100%, Disagree: 0%, Abstain: 0% (Unanimous, Strongest Consensus)

### **RATIONALE**

Drains are plastic tubes that are used to prevent the formation of surgical site serous pockets (seromas) and blood pockets (hematomas), both of which may act as a space for potential surgical site infection in addition to causing pain [1]. In orthopaedics, drains are commonly used to reduce collection of fluid around the joint and potentially reduce subsequent SSIs despite little evidence showing their benefit [2,3]. The utilization of closed suction drainage systems in primary arthroplasty has been debated for many years. Anecdotally, the benefits of a drain are thought to be prevention of hematoma formation and therefore improved wound healing and decreased infection rates [2]. The main disadvantage is the creation of a communication between the deep tissues and the surrounding environment, providing a conduit for bacterial contamination [2]. In fact, drains are known to be risk factor for SSIs [4]. Patel et al. have reported a relative risk increase in SSIs of 42% with each additional day of wound drainage [5]. Despite the scarcity of evidence supporting their benefit and known risks, orthopaedic surgeons continue to utilize drains in their procedures [6].

PJI rates after elective total joint replacement are reported between 1-2% [7,8]. However, the risk of PJI following EPR is even higher with rates ranging between 10-25% [9,10]. Because drains are a known risk factor for SSIs, their use in orthopaedic oncologic procedures is of particular concern. Oncology patients are at increased risk because many of them are immunocompromised. Secondly, this patient population often develops a large dead space after tumor resection necessitating placement of a surgical drain to prevent hematoma formation in the postoperative period.

A large meta-analysis of all randomized controlled trials of drain use in orthopaedic surgery was published by Parker et al. in 2004. They found no significant difference between wounds treated with and without drains with respect to the development of wound infection, wound hematoma or reoperations for wound complications [11]. However, the drained wounds did have a significantly greater need for blood transfusion [11]. These overall findings have been shown in numerous other studies of patients undergoing arthroplasty, general surgical and orthopaedic trauma procedures [12-14].

In 2007, a Cochrane Systematic Review was conducted to assess the utilization of drains in orthopaedic surgery. Thirty-six studies involving 5,464 patients with 5,697 surgical wounds were included [2]. Many orthopaedic procedures were utilized, although there was no specific mention of oncologic patients in the review. Pooling of results showed no statistically significant difference in the incidence of wound infection, hematoma, dehiscence or reoperation between those who had a drain and those who did not [2]. The incidence of SSI was 1.9% in patients who received a closed suction drain and 2.4% in those who did not [2]. Blood transfusions were required

more frequently in those who received drains [2]. Previous literature has found an association between blood transfusion and infection in both the arthroplasty and orthopaedic oncology literature [15,16]. Despite the described findings of previous literature and the increased blood transfusions in the drain group, an independent relationship between drain placement and infection was not found in the Cochrane review [2].

In terms of the timing of drain removal, the literature remains inconclusive. In their prospective study of 214 uninfected orthopaedic operations, Sankar et al. found no significant correlation between wound infection and duration of drain retention [17]. Another prospective study examined total hip and knee arthroplasty patients who all received suction drains. Upon drain removal, the patients' drain-sites were swabbed and the drain tips were sent for culture [18]. This study demonstrated that the likelihood of bacterial colonization increased while wound drainage decreased over time; however, this does not necessarily translate to clinical development of SSI and their recommendation for removal at 24 hours must be cautiously considered [18].

Willett et al. attempted to further examine the timing of drain removal by removing drains at 24, 48 or 72 hours and culturing the aspirates taken from the drain tip; they found increasing rates of positive cultures in the groups where the drain was removed later. However, this difference was not statistically significant [19]. The authors of this study conclude that their data affirm the risk of retrograde influx of organisms along the drain track if the drain remains in place longer than 24 hours [19]. However, because their results were not statistically significant, they were incorrectly drawing this conclusion.

From the arthroplasty and surgical literature, there is no evidence of benefit to extending antibiotic duration until drains are removed; however, this has not specifically been evaluated in a musculoskeletal oncology patient population [20,21]. Due to the scarcity of quality literature in this area and the lack of evidence suggesting a relationship between utilization of drains and SSI, an evidence-based recommendation regarding the use of drains and the timing of their removal cannot be made for orthopaedic oncology patients.

### **REFERENCES**

- [1] Durai R, Mownah A, Ng PCH. Use of drains in surgery: a review. *J Perioper Pract.* 2009;19:180-186. doi:10.1177/175045890901900603.
- [2] Parker MJ, Livingstone V, Clifton R, McKee A. Closed suction surgical wound drainage after orthopaedic surgery. *Cochrane Database Syst Rev.* 2007;CD001825. doi:10.1002/14651858.CD001825.pub2.
- [3] Gaines RJ, Dunbar RP. The use of surgical drains in orthopedics. *Orthopedics.* 2008;31:702-705.
- [4] Rossi B, Zoccali C, Toma L, Ferraresi V, Biagini R. Surgical site infections in treatment of musculoskeletal tumors: experience from a single oncologic

- orthopedic institution. ResearchGate 2016. [https://www.researchgate.net/publication/304744960\\_Surgical\\_Site\\_Infections\\_in\\_Treatment\\_of\\_Musculoskeletal\\_Tumors\\_Experience\\_from\\_a\\_Single\\_Oncologic\\_Orthopedic\\_Institution](https://www.researchgate.net/publication/304744960_Surgical_Site_Infections_in_Treatment_of_Musculoskeletal_Tumors_Experience_from_a_Single_Oncologic_Orthopedic_Institution) (accessed July 18, 2018).
- [5] Patel VP, Walsh M, Sehgal B, Preston C, DeWal H, Di Cesare PE. Factors associated with prolonged wound drainage after primary total hip and knee arthroplasty. *J Bone Joint Surg Am.* 2007;89:33-38. doi:10.2106/JBJS.F.00163.
  - [6] Chandratreya A, Giannikas K, Livesley P. To drain or not drain: literature versus practice. *J R Coll Surg Edinb.* 1998;43:404-406.
  - [7] Ong KL, Kurtz SM, Lau E, Bozic KJ, Berry DJ, Parvizi J. Prosthetic joint infection risk after total hip arthroplasty in the Medicare population. *J Arthroplasty.* 2009;24:105-109. doi:10.1016/j.arth.2009.04.027.
  - [8] Kurtz SM, Ong KL, Lau E, Bozic KJ, Berry DJ, Parvizi J. Prosthetic joint infection risk after TKA in the Medicare population. *Clin Orthop Relat Res.* 2010;468:52-56. doi:10.1007/s11999-009-1013-5.
  - [9] Grimer RJ, Aydin BK, Wafa H, Carter SR, Jeys L, Abudu A, et al. Very long-term outcomes after endoprosthetic replacement for malignant tumours of bone. *Bone Joint J.* 2016;98-B:857-864. doi:10.1302/0301-620X.98B6.37417.
  - [10] Jeys L, Grimer R. The long-term risks of infection and amputation with limb salvage surgery using endoprostheses. *Recent Results Cancer Res.* 2009;179:75-84.
  - [11] Parker MJ, Roberts CP, Hay D. Closed suction drainage for hip and knee arthroplasty. A meta-analysis. *J Bone Joint Surg Am.* 2004;86-A:1146-1152.
  - [12] Hsu JR, Stinner DJ, Rosenzweig SD, Salinas J, Dickson KF. Is there a benefit to drains with a Kocher-Langenbeck approach? A prospective randomized pilot study. *J Trauma.* 2010;69:1222-1225. doi:10.1097/TA.0b013e3181bc78cb.
  - [13] Walmsley PJ, Kelly MB, Hill RMF, Brenkel I. A prospective, randomised, controlled trial of the use of drains in total hip arthroplasty. *J Bone Joint Surg Br.* 2005;87:1397-1401. doi:10.1302/0301-620X.87B10.16221.
  - [14] Reiffel AJ, Barie PS, Spector JA. A multi-disciplinary review of the potential association between closed-suction drains and surgical site infection. *Surg Infect (Larchmt).* 2013;14:244-269. doi:10.1089/sur.2011.126.
  - [15] Tan MH, Mankin HJ. Blood transfusion and bone allografts. Effect on infection and outcome. *Clin Orthop Relat Res.* 1997;207-214.
  - [16] Pulido L, Ghanem E, Joshi A, Purtill JJ, Parvizi J. Periprosthetic joint infection: the incidence, timing, and predisposing factors. *Clin Orthop Relat Res.* 2008;466:1710-1715. doi:10.1007/s11999-008-0209-4.
  - [17] Sankar B, Ray P, Rai J. Suction drain tip culture in orthopaedic surgery: a prospective study of 214 clean operations. *Int Orthop.* 2004;28:311-314. doi:10.1007/s00264-004-0561-2.
  - [18] Drinkwater CJ, Neil MJ. Optimal timing of wound drain removal following total joint arthroplasty. *J Arthroplasty.* 1995;10:185-189.
  - [19] Willett KM, Simmons CD, Bentley G. The effect of suction drains after total hip replacement. *J Bone Joint Surg Br.* 1988;70:607-610.
  - [20] Bratzler DW, Dellinger EP, Olsen KM, Perl TM, Auwaerter PG, Bolon MK, et al. Clinical practice guidelines for antimicrobial prophylaxis in surgery. *Surg Infect (Larchmt).* 2013;14:73-156. doi:10.1089/sur.2013.9999.
  - [21] Bratzler DW, Houck PM, Richards C, Steele L, Dellinger EP, Fry DE, et al. Use of antimicrobial prophylaxis for major surgery: baseline results from the National Surgical Infection Prevention Project. *Arch Surg.* 2005;140:174-182. doi:10.1001/archsurg.140.2.174.

● ● ● ● ●

**Authors:** Richard O'Donnell, John Strony

### QUESTION 3: Does the type of fixation (cemented vs. uncemented) of an oncologic endoprosthesis influence the incidence of subsequent surgical site infection/periprosthetic joint infection (SSI/PJI)?

**RECOMMENDATION:** There is conflicting evidence surrounding this topic. Multiple studies have demonstrated superiority with cemented fixation of an oncologic endoprosthesis while others have suggested superiority with uncemented fixation. Therefore, the choice of the method of fixation should be made on the basis of all clinical indications, other than the influence of fixation on subsequent SSI/PJI.

**LEVEL OF EVIDENCE:** Limited

**DELEGATE VOTE:** Agree: 100%, Disagree: 0%, Abstain: 0% (Unanimous, Strongest Consensus)

#### RATIONALE

Limb salvage surgery has become the treatment of choice for musculoskeletal cancers due to advances within the field of orthopaedic oncology. The use of an oncologic endoprosthesis has become the procedure of choice in limb salvage surgery. Though there are many benefits in utilizing an endoprosthesis, the development of subsequent infection is one of the most common and feared complications.

Multiple studies have been conducted to examine the risk of postoperative infection associated with the type of fixation (cemented vs. uncemented). Moreover, the approval and universal use of antibiotic-impregnated cement has altered the landscape as it relates to the risk and type of infection.

A systemic review of 40 studies examining distal femoral replacement (DFR) cases and proximal tibial replacement (PTR) cases showed mixed results. One hundred and nine (5.8%) of 1,894 cemented DFR cases became infected while 65 (9.0%) of 721 uncemented DFR cases became infected. This difference was found to be statistically significant [1]. For cemented DFR replacements, linear regression analysis showed that the risk of infection increased over time ( $p < 0.001$ ), but the risk for infection in uncemented DFR implants did not increase over time. The same systemic review showed that 109 (15.2%) of 716 cemented PTR cases became infected while 56 (14.1%) of 396 uncemented PTR cases became infected; this difference was not found to be statistically significant. The incidence

of infection in PTR cases did not increase over time, regardless of the fixation method [1].

Pala et al. [2] reported that 20 (9.1%) of 220 endoprostheses originally implanted in patients with either a lower extremity primary bone tumor or metastatic disease became infected. Of these 20 cases, 12 (10.3%) were cemented and eight (7.7%) were uncemented. In addition, survival of cemented endoprostheses to infection was 68% at 60 months, while survival of the uncemented endoprostheses was 82% at 60 months [2]. Finally, in both univariate and multivariate analyses, the only variable that was found to be a predictor of survival was uncemented fixation [2].

The infection rates of endoprostheses vary widely in the literature. Studies investigating the infection rate after cemented fixation of an endoprosthetic device yielded an infection rate ranging from 5.2% to 21.9% [3-7]; studies investigating the infection rate after uncemented fixation yielded rates ranging from 9.7% to 12% [8-10]. A condition of equipoise exists resulting from the conflicting data supporting cemented or uncemented fixation and the incidence of subsequent SSI/PJI.

#### REFERENCES

- [1] Haijie L, Dasen L, Tao J, Yi Y, Xiaodong T, Wei G. Implant survival and complication profiles of endoprostheses for treating tumor around the knee in

- adults: a systematic review of the literature over the past 30 years. *J Arthroplasty*. 2018;33:1275-1287.e3. doi:10.1016/j.arth.2017.10.051.
- [2] Pala E, Mavrogenis AF, Angelini A, Henderson ER, Douglas Letson G, Ruggieri P. Cemented versus cementless endoprostheses for lower limb salvage surgery. *J BUON*. 2013;18:496-503.
  - [3] Ahlmann ER, Menendez LR, Kermani C, Gotha H. Survivorship and clinical outcome of modular endoprosthetic reconstruction for neoplastic disease of the lower limb. *J Bone Joint Surg Br*. 2006;88:790-795. doi:10.1302/0301-620X.88B6.17519.
  - [4] Bickels J, Wittig JC, Kollender Y, Henshaw RM, Kellar-Graney KL, Meller I, et al. Distal femur resection with endoprosthetic reconstruction: a long-term followup study. *Clin Orthop Relat Res*. 2002;225-235.
  - [5] Zeegen EN, Aponte-Tinao LA, Hornicek FJ, Gebhardt MC, Mankin HJ. Survivorship analysis of 141 modular metallic endoprostheses at early followup. *Clin Orthop Relat Res*. 2004;239-250.
  - [6] Sharma S, Turcotte RE, Isler MH, Wong C. Experience with cemented large segment endoprostheses for tumors. *Clin Orthop Relat Res*. 2007;459:54-59. doi:10.1097/BLO.0b013e3180514c8e.
  - [7] Unwin PS, Cannon SR, Grimer RJ, Kemp HB, Sneath RS, Walker PS. Aseptic loosening in cemented custom-made prosthetic replacements for bone tumours of the lower limb. *J Bone Joint Surg Br*. 1996;78:5-13.
  - [8] Gosheger G, Gebert C, Ahrens H, Streitbueger A, Winkelmann W, Harges J. Endoprosthetic reconstruction in 250 patients with sarcoma. *Clin Orthop Relat Res*. 2006;450:164-171. doi:10.1097/01.blo.0000233978.36831.39.
  - [9] Mittermayer F, Krepler P, Dominkus M, Schwameis E, Sluga M, Heinzl H, et al. Long-term followup of uncemented tumor endoprostheses for the lower extremity. *Clin Orthop Relat Res*. 2001;167-177.
  - [10] Griffin AM, Parsons JA, Davis AM, Bell RS, Wunder JS. Uncemented tumor endoprostheses at the knee: root causes of failure. *Clin Orthop Relat Res*. 2005;438:71-79.

● ● ● ● ●

**Authors:** Takeshi Morii, Timothy L. Tan

## QUESTION 4: Does the use of incise draping with antibacterial agents (iodine) influence the risk for subsequent surgical site infection/periprosthetic joint infection (SSI/PJI) in patients undergoing musculoskeletal tumor surgeries?

**RECOMMENDATION:** There is some evidence claiming that antimicrobial-impregnated incise drapes result in a reduction in bacterial contamination at the surgical site. However, there is little evidence to demonstrate that it results in a subsequent reduction in the incidence of SSI and/or PJI.

**LEVEL OF EVIDENCE:** Limited

**DELEGATE VOTE:** Agree: 100%, Disagree: 0%, Abstain: 0% (Unanimous, Strongest Consensus)

### RATIONALE

Surgical incise drapes are often used by surgeons to reduce bacterial recolonization of the surgical site with host flora that may potentially predispose the patient to subsequent infection. Furthermore, it is important to differentiate antimicrobial-impregnated drapes from non-impregnated drapes as the addition of an antimicrobial agent, such as iodophor, may have a different effect on the rate of recolonization. The rationale behind the antimicrobial drape is that the incise drape can act as a physical barrier to block bacterial proliferation on the skin and potential entry into the surgical wound.

Multiple studies have demonstrated that incise drapes can result in a reduction in bacterial recolonization. In a prospective randomized controlled trial of 101 hips undergoing hip preservation surgery, Rezapoor et al. found that iodine-impregnated drapes resulted in a significant reduction (12.0% vs. 27.4%) in bacterial colonization compared to those without drapes [1]. Furthermore, Milandt et al. reported that the use of iodine-containing incision drapes did not increase bacterial recolonization in simulated total knee arthroplasty [2]. Dewan et al. reported that the use of an iodophor-impregnated plastic incise drape in abdominal surgery reduced the contamination of the wound [3]. Casey et al. evaluated the antimicrobial efficacy of an iodine-impregnated incise drape against methicillin-resistant *S. aureus* (MRSA) in a skin model and concluded that it had detectable antimicrobial activity [4].

While there is evidence to suggest that impregnated incise drapes result in a reduction of bacterial colonization, there is conflicting evidence demonstrating that impregnated incise drapes result in a significant decrease in the infection rate. Ritter et al. demonstrated a considerably low rate of SSI incidence (0.46%) in total arthroplasties performed with an antimicrobial incise drape [5]. In addition, Yoshimura et al. found that the lack of an iodophor-impregnated drape was a significant risk factor for

wound infection after liver resection [6]. In contrast, a randomized study by Dewan et al. suggested that iodine-impregnated drapes did not result in a significant reduction in SSI rate in abdominal and cardiac surgery [3]. Furthermore, a randomized study by Segal and Anderson showed only a tendential reduction in the rate of SSIs by iodophor-impregnated adhesive drapes in high risk cardiac surgery [7]. Additionally, no SSIs were observed in a retrospective review of 581 patients undergoing anterior cervical fusions without iodophor-impregnated incision drapes. It was concluded that the use of iodophor-impregnated incision drapes during anterior cervical fusion was not needed [8].

In a Cochrane review of 3,082 patients, Webster et al. found that a higher proportion of patients developed surgical site infection with plastic drapes than patients in whom no drapes were used ( $p = 0.03$ ) [9]. However, no difference was found when iodophor-impregnated drapes were used (rate ratio (RR) 1.03, 95% confidence interval (CI) 0.06 to 1.66,  $p = 0.89$ ), which further highlights the importance of discriminating between antimicrobial and regular plastic incise drapes. In the World Health Organization guideline [10], four of the above-mentioned studies (one randomized-controlled trial (RCT) [7], one quasi-RCT [11] and two observational studies [6,12]) were identified that assessed the effect of using single-use adhesive incise drapes to reduce SSI. They commented that the two RCTs showed the use of antimicrobial-impregnated incise drapes may have some adverse effect, but the effect estimate was not statistically different from the control group. Furthermore, they noted that the observational studies reported that there may be a benefit in using antimicrobial-impregnated incise drapes, but the effect was not statistically different from the control group. They concluded that the quality of evidence for these comparisons was very low for both the randomized control trials and the observational studies due to the risk of bias and imprecision or inconsistency.

There is an extensive number of publications demonstrating that the use of antimicrobial-impregnated incise draping leads to a lower incidence of surgical site contamination. Studies demonstrating the beneficial effect of incise draping in reduction of surgical site infection, especially after tumor surgery, are lacking.

## REFERENCES

- [1] Rezapoor M, Tan TL, Maltenfort MG, Parvizi J. Incise draping reduces the rate of contamination of the surgical site during hip surgery: a prospective, randomized trial. *J Arthroplasty*. 2018;33(6):1891-1895. doi:10.1016/j.arth.2018.01.013.
- [2] Milandt N, Nymark T, Jørn Kolmos H, Emmeluth C, Overgaard S. Iodine-impregnated incision drape and bacterial recolonization in simulated total knee arthroplasty. *Acta Orthop*. 2016;87:380-385. doi:10.1080/17453674.2016.1180577.
- [3] Dewan PA, Van Rij AM, Robinson RG, Skeggs GB, Fergus M. The use of an iodophor-impregnated plastic incise drape in abdominal surgery—a controlled clinical trial. *Aust N Z J Surg*. 1987;57:859-863.
- [4] Casey AL, Karpanen TJ, Nightingale P, Conway BR, Elliott TSJ. Antimicrobial activity and skin permeation of iodine present in an iodine-impregnated surgical incise drape. *J Antimicrob Chemother*. 2015;70:2255-2260. doi:10.1093/jac/dkv100.
- [5] Ritter MA, Campbell ED. Retrospective evaluation of an iodophor-incorporated antimicrobial plastic adhesive wound drape. *Clin Orthop Relat Res*. 1988;307-308.
- [6] Yoshimura Y, Kubo S, Hirohashi K, Ogawa M, Morimoto K, Shirata K, et al. Plastic iodophor drape during liver surgery operative use of the iodophor-impregnated adhesive drape to prevent wound infection during high risk surgery. *World J Surg*. 2003;27:685-688. doi:10.1007/s00268-003-6957-0.
- [7] Segal CG, Anderson JJ. Preoperative skin preparation of cardiac patients. *AORN J*. 2002;76:821-828.
- [8] Chin KR, London N, Gee AO, Bohlman HH. Risk for infection after anterior cervical fusion: prevention with iodophor-impregnated incision drapes. *Am J Orthop*. 2007;36:433-435.
- [9] Webster J, Alghamdi A. Use of plastic adhesive drapes during surgery for preventing surgical site infection. *Cochrane Database Syst Rev*. 2015;CD006353. doi:10.1002/14651858.CD006353.pub4.
- [10] WHO | Global guidelines on the prevention of surgical site infection. WHO n.d. <http://www.who.int/gpsc/ssi-prevention-guidelines/en/> (accessed November 19, 2017).
- [11] Al-Qahtani SM, Al-Amoudi HM, Al-Jehani S, Ashour AS, Abd-Hammad MR, Tawfik OR, et al. Post-appendectomy surgical site infection rate after using an antimicrobial film incise drape: a prospective study. *Surg Infect (Larchmt)*. 2015;16:155-158. doi:10.1089/sur.2013.188.
- [12] Swenson BR, Camp TR, Mulloy DP, Sawyer RG. Antimicrobial-impregnated surgical incise drapes in the prevention of mesh infection after ventral hernia repair. *Surg Infect (Larchmt)*. 2008;9:23-32. doi:10.1089/sur.2007.021.



**Authors:** Aare Märtson, Irene Kalbian

## QUESTION 5: Does the use of soft tissue attachment meshes increase the risk for subsequent periprosthetic joint infection (PJI) in patients undergoing oncologic endoprosthetic reconstruction?

**RECOMMENDATION:** The current literature indicates that there is no increased risk of PJI in this patient population with the use of soft tissue attachment meshes. However, there are few studies directly comparing the use of mesh vs. not using mesh in comparable tumors/surgical locations, so further comprehensive study on the topic is necessary to say with reasonable certainty that there is no connection.

**LEVEL OF EVIDENCE:** Limited

**DELEGATE VOTE:** Agree: 100%, Disagree: 0%, Abstain: 0% (Unanimous, Strongest Consensus)

## RATIONALE

The reported infection incidence after tumor resection and replacement with an endoprosthesis varies widely in the literature, ranging from 7.8% to 25% [1-3]. Tumor type and surgical site have a significant influence on the infection incidence [3,4]. Despite the variation reported in the literature, the infection burden for these procedures is much greater than that of primary joint replacement surgery for which the infection rate of hips and knees is estimated at 1% [5].

Infection in endoprosthetic reconstruction cases has been attributed to multiple sources, one of which is the use of surgical mesh. Surgical mesh has been suggested to act as a vehicle for infection. This risk is increased when the mesh is used alongside a large implant or neoadjuvant chemotherapy. Henderson et al. investigated complication incidence in a series of 534 endoprosthetic failures and found that infection was the most common mode of failure [4]. Cho et al. examined risk factors related to infection in a cohort of 62 patients who underwent proximal tibial endoprosthetic reconstruction. Prostheses were removed due to infection in 25.8% of the patients; however, application of synthetic mesh to stabilize the patella was not found to be a significant risk factor, nor was chemotherapy [1]. A 2017 study investigated patient outcomes using BARD® mesh for endoprosthetic reconstruction and reported that only one case of deep infection and two cases of superficial infection developed out of 51 patients [6]. A systematic review of reconstruction

techniques after resection of proximal humeral tumors found that megaprosthesis with mesh had an infection rate of 4%, which was between the rates of hemiarthroplasty (0%) and reverse shoulder arthroplasty (9%) [7].

Polyethylenterephthalate mesh, known as a Trevira® tube, is a mesh option used for endoprosthetic reconstruction. A 2001 study of 69 megaprotheses implants with Trevira tube for soft tissue reconstruction reported that there was no significant increase in the rate of infection compared to implantation without a Trevira tube [8]. Similarly, Maccauro et al. examined a cohort of 36 patients with solitary bone metastases who underwent resection and endoprosthetic reconstruction, of which 20 of the patients received a Trevira tube. They also detected no significant difference in infection rate between patients who did and did not receive a Trevira tube [9]. Additionally, Schmolders et al. determined that replacement of the proximal humerus using a Trevira tube in combination with a modular endoprosthesis is a safe and viable treatment option for both bone tumors and metastases. They observed no statistically significant increased risk of infection by using a Trevira tube, even among immunosuppressed patients [10].

Surgical meshes for reconstruction of abdominal wall hernias and groin region hernias have been successfully used since the 1940s [11]. While abdominal hernia repairs do not incur the additional



infection risks of endoprosthesis implantation and immunosuppressive effects of neoadjuvant therapy, patient outcomes using synthetic mesh for abdominal hernia repair have been well studied and provide some insight regarding infection rates associated with the use of mesh. A recent meta-analysis of 10 randomized controlled trials comparing abdominal hernia surgery outcomes using mesh vs. surgical suture detected no significant difference in infection rates between the 2 groups. However, the mesh group did demonstrate significantly lower incidence of recurrent hernia than the surgical suture group, leading the authors to conclude synthetic mesh was a highly efficacious repair technique [12].

In summary, the published literature suggested little or no association between the use of mesh for soft tissue attachment with endoprosthetic reimplantation and development of subsequent PJI. Further study is needed before it can be conclusively determined that the use of soft tissue attachment meshes does not increase the risk for subsequent infection in patients undergoing oncologic endoprosthetic reconstruction. Future investigation should utilize larger cohorts and control for tumor type and location so that the use of mesh can be better isolated as the variable of interest.

## REFERENCES

- [1] Cho W, Song W, Jeon D, Kong C, Kim J, Lee S. Cause of infection in proximal tibial endoprosthetic reconstructions. *Arch Orthop Trauma Surg.* 2012;132:163-169.
- [2] Gosheger G, Gebert C, Ahrens H, Streibueger A, Winkelmann W, Harges J. Endoprosthetic reconstruction in 250 patients with sarcoma. *Clin Orthop Relat Res.* 2006;450:164-171.
- [3] Rossi B, Zoccali C, Toma L, Ferraresi V, Biagini R. Surgical site infections in treatment of musculoskeletal tumors: experience from a single oncologic orthopedic institution. *J Orthop Oncol.* 2016;2:1. doi:10.4172/2472-016X.1000108.
- [4] Henderson E, Groundland J, Pala E, Dennis J, Wooten R, Cheong D, et al. Failure mode classification for tumor endoprostheses: retrospective review of five institutions and a literature review. *J Bone Joint Surg Am.* 2011;93:418-429.
- [5] Springer B, Cahue S, Etkin C, Lewallen D, McGrory B. Infection burden in total hip and knee arthroplasties: an international registry-based perspective. *Arthroplast Today.* 2017;3:137-140.
- [6] Lin J, Chen R, Yan W, Chen D. Enhancing soft-tissue reattachment with artificial mesh in joint endoprosthetic reconstruction for bone tumors. *Zhonghua Zhong Liu Za Zhi.* 2017;39:540-544. doi:10.3760/cma.j.issn.0253-3766.2017.07.013.
- [7] Dubina A, Shiu B, Gilotra M, Hasan SA, Lerman D, Ng VY. What is the optimal reconstruction option after the resection of proximal humeral tumors? A systematic review. *Open Orthop J.* 2017;11:203-211. doi:10.2174/1874325001711010203.
- [8] Gosheger G, Hillmann A, Lindner N, Rodl R, Hoffmann C, Burger H, et al. Soft tissue reconstruction of megaprotheses using a trevira tube. *Clin Orthop Relat Res.* 2001;393:264-271.
- [9] Maccauro G, Piccioli A, Barreca S, Fenga D, Rosa M. Local resections and prosthetic reconstructions in solitary bone metastases of the limbs according to histotypes. *J Integr Oncol.* 2016;5. doi:10.4172/2329-6771.1000161.
- [10] Schmolders J, Koob S, Schepers P, Kehrer M, Frey S, Wirtz C. Silver-coated endoprosthetic replacement of the proximal humerus in case of tumour—is there an increased risk of periprosthetic infection by using a trevira tube? *Int Orthop.* 2016;41:423-428. doi:10.1007/s00264-016-3329-6.
- [11] Nau P, J Clark C, Fisher M, Walker G, Needleman BJ, Ellison EC, et al. Modified rives-stoppa repair for abdominal incisional hernias. *Health.* 2010;2(2):162-169. doi:10.4236/health.2010.22024.
- [12] López-Cano M, Martín-Domínguez LA, Pereira JA, Armengol-Carrasco M, García-Alamino JM. Balancing mesh-related complications and benefits in primary ventral and incisional hernia surgery. A meta-analysis and trial sequential analysis. *PLoS One.* 2018;13:e0197813. doi:10.1371/journal.pone.0197813.

**Authors:** R. Lor Randall, Antonios I. Papadopoulos, John S. Groundland

## QUESTION 6: Should endoprosthesis and/or allograft bone be soaked in antibiotic solution or antiseptic solutions prior to implantation in patients?

**RESPONSE:** Unknown. There is no evidence to suggest that the use of a pre-implantation antibiotic or antiseptic soak of an endoprosthesis or massive allograft would reduce the rate of surgical site infection/periprosthetic joint infection (SSI/PJI).

**LEVEL OF EVIDENCE:** Consensus

**DELEGATE VOTE:** Agree: 100%, Disagree: 0%, Abstain: 0% (Unanimous, Strongest Consensus)

## RATIONALE

In the oncologic literature, infection rates following metallic endoprostheses and bulk allograft surgery are high. In a systematic review, Henderson et al. found the rate of infection-related failure of endoprostheses to be 7.4%, when all anatomic locations were taken into account. Proximal tibia replacements and total femur replacements were noted to be at particular risk for infection, requiring revision surgery in 19.7% and 17.5% of cases, respectively [1]. In a systematic review of pediatric oncology patients, Groundland et al. found an infection rate of 12.9% and 17.1% when bulk osteoarticular allografts were used to reconstruct the distal femur and proximal tibia, respectively [2].

While not fully understood or rigorously investigated, the causes of these high rates of infection are likely multi-factorial, including extensive surgical dissections and resections, substantial blood loss, implantation of large constructs with foreign material and, in the case of oncology patients, a potentially immunosuppressed host.

Any measure that leads to decreased infection rates of metallic endoprosthesis and massive allograft reconstruction would be desirable. Given the prevalence of the problem and the severity of the consequences of deep infection, even weak evidence supporting a decrease in infection rates would be worth considering. While a few interventions have been noted to be beneficial, as reported in retrospective case series, no rigorous, prospective studies have been completed in this population [3-8]. Regarding the question above, there is no evidence to support or reject the use of a pre-implantation antiseptic soak of the endoprosthesis (or allograft). Local application of an antibiotic solution (e.g., gentamicin) around prosthesis before closing the incision in conjunction with a parenteral agent as antibiotic prophylaxis is routine practice in some institutions [9]. However, antibiotic solutions have been found to offer no advantage over saline in the removal of bacteria from bone, titanium or stainless steel. In addition, there

are no efficacy data to support the use of antibiotic soaks in procedures with sterile prosthesis insertion [10,11]. There are no high quality trials testing the effectiveness of antiseptic soaking of prosthesis before implantation [12]. Moreover, antiseptics could exert changes in materials used for total arthroplasty (e.g., titanium alloy or hydroxyapatite), cause chondrolysis or pose cytotoxicity to human fibroblasts and osteoblasts [13,14].

Conceptually, a pre-implantation soak would decrease the bacterial load on the implant immediately prior to implantation, thereby reducing the risk of an infection caused by direct seeding of the wound bed by the implant itself. In an *in vitro* study bone fragments soaked with a solution of gentamicin or vancomycin for 30 minutes were loaded with an antibiotic concentration, 5-fold the minimum inhibitory concentration (MIC) values would be needed to provoke bacterial regression [15]. It has been also shown that *in vitro* decontamination of bone allografts contaminated with coagulase-negative Staphylococci is feasible after soaking bone with gentamicin or rifampicin for 60 minutes [16]. However, clinical studies are lacking, and there are no randomized controlled trials or systematic reviews that have evaluated soaking endoprosthesis or allograft bone in antibiotic or antiseptic solutions before implantation for the prevention of surgical site infections [17]. Two facts belie this practice. First, there is no published evidence that sterilized implants (endoprosthesis or allograft) routinely become colonized or contaminated from their unpackaging to implantation. Second, most infections in endoprosthesis and massive allograft surgery do not manifest in the perioperative period; rather, the average time to failure due to infection occurs years after the index surgery. In their report of 2,174 endoprosthesis surgeries, Henderson et al. reported an overall time revision surgery due to infection of 47 months, with a non-normally distributed standard deviation of 69 months [1]. The anatomic location with the fastest time to infection-driven revision was the elbow, occurring at a mean of 16 months, while the proximal humerus had an infection time of 80 months. A pre-implant soak would have no theoretical impact on these late infections.

## REFERENCES

- [1] Henderson ER, Groundland JS, Pala E, Dennis JA, Wooten R, Cheong D, et al. Failure mode classification for tumor endoprostheses: retrospective review

- of five institutions and a literature review. *J Bone Joint Surg Am.* 2011;93:418–429. doi:10.2106/JBJS.00834.
- [2] Groundland JS, Ambler SB, Houskamp LDJ, Orriola JJ, Binitie OT, Letson GD. Surgical and functional outcomes after limb-preservation surgery for tumor in pediatric patients: a systematic review. *JBJS Surg.* 2016;4(2). doi:10.2106/JBJS.RVW.0.00013.
- [3] Lozano-Calderón SA, Swaim SO, Federico A, Anderson ME, Gebhardt MC. Predictors of soft-tissue complications and deep infection in allograft reconstruction of the proximal tibia. *J Surg Oncol.* 2016;113:811–817. doi:10.1002/jso.24234.
- [4] Campanacci M, Bacci G, Bertoni F, Picci P, Minuttillo A, Franceschi C. The treatment of osteosarcoma of the extremities: twenty year's experience at the Istituto Ortopedico Rizzoli. *Cancer.* 1981;48:1569–1581.
- [5] Donati F, Di Giacomo G, D'Adamio S, Ziranu A, Careri S, Rosa M, et al. Silver-coated hip megaprosthesis in oncological limb salvage surgery. *Biomed Res Int.* 2016;2016:9079041. doi:10.1155/2016/9079041.
- [6] Ghert M, Deheshi B, Holt G, Randall RL, Ferguson P, Wunder J, et al. Prophylactic antibiotic regimens in tumour surgery (PARITY): protocol for a multi-centre randomised controlled study. *BMJ Open.* 2012;2. doi:10.1136/bmjopen-2012-002197.
- [7] Zamborsky R, Svec A, Bohac M, Kilian M, Kokavec M. Infection in bone allograft transplants. *Exp Clin Transplant.* 2016;14:484–490.
- [8] Aponte-Tinao LA, Ayerza MA, Muscolo DL, Farfalli GL. What are the risk factors and management options for infection after reconstruction with massive bone allografts? *Clin Orthop Relat Res.* 2016;474:669–673. doi:10.1007/s11999-015-4353-3.
- [9] Song Z, Borgwardt L, Høiby N, Wu H, Sørensen TS, Borgwardt A. Prosthesis infections after orthopedic joint replacement: the possible role of bacterial biofilms. *Orthop Rev (Pavia).* 2013;5:65–71. doi:10.4081/or.2013.e14.
- [10] Guidelines on antibiotic prophylaxis in surgery: single dose before surgery. Montefiore Medical Center, Albert Einstein College of Medicine. [https://www.einstein.yu.edu/uploadedFiles/departments/medicine/Updated%20Surgical%20PPX%20Poster%2011%202017\(1\).pdf](https://www.einstein.yu.edu/uploadedFiles/departments/medicine/Updated%20Surgical%20PPX%20Poster%2011%202017(1).pdf). 2017.
- [11] McHugh SM, Collins CJ, Corrigan MA, Hill ADK, Humphreys H. The role of topical antibiotics used as prophylaxis in surgical site infection prevention. *J Antimicrob Chemother.* 2011;66:693–701. doi:10.1093/jac/ckr009.
- [12] George J, Klika AK, Higuera CA. Use of chlorhexidine preparations in total joint arthroplasty. *J Bone Joint Infect.* 2017;2:15–22. doi:10.7150/jbji.16934.
- [13] Shigematsu M, Kitajima M, Ogawa K, Higo T, Hotokebuchi T. Effects of hydrogen peroxide solutions on artificial hip joint implants. *J Arthroplasty.* 2005;20:639–646. doi:10.1016/j.arth.2005.01.010.
- [14] Lu M, Hansen EN. Hydrogen peroxide wound irrigation in orthopaedic surgery. *J Bone Joint Infect.* 2017;2:3–9. doi:10.7150/jbji.16690.
- [15] Shah MR, Patel RR, Solanki RV, Gupta SH. Estimation of drug absorption in antibiotic soaked bone grafts. *Indian J Orthop.* 2016;50:669–676. doi:10.4103/0019-5413.193486.
- [16] Saegeman VSM, Ectors NL, Lismont D, Verduyck B, Verhaegen J. Effectiveness of antibiotics and antiseptics on coagulase-negative staphylococci for the decontamination of bone allografts. *Eur J Clin Microbiol Infect Dis.* 2009;28:813–816. doi:10.1007/s10096-009-0715-7.
- [17] Berrios-Torres SI, Umscheid CA, Bratzler DW, Leas B, Stone EC, Kelz RR, et al. Centers for Disease Control and Prevention Guideline for the Prevention of Surgical Site Infection, 2017. *JAMA Surg.* 2017;152:784–791. doi:10.1001/jamasurg.2017.0904.



**Authors:** Muhammad Ather Siddiqi, A. Mazhar Tokgözoğlu

## QUESTION 7: Should a coated prosthesis (silver/iodine) be used for reconstruction of patients undergoing primary bone tumor resection?

**RECOMMENDATION:** Yes, silver coating and iodine coating of prosthesis show good results in prevention of infection after reconstruction following primary tumor resection.

**LEVEL OF EVIDENCE:** Moderate

**DELEGATE VOTE:** Agree: 100%, Disagree: 0%, Abstain: 0% (Unanimous, Strongest Consensus)

## RATIONALE

Megaprosthesis has been used to reconstruct limbs and large skeletal defects after resection of bone tumors for many decades. A significant problem is the higher rate of infection as compared to an infection rate of <1% after a standard primary arthroplasty procedure.

Many factors have been cited in literature which include length of surgery, OR environment, blood transfusions, soft tissue available for coverage and segment involved, e.g., tibia vs. femur. The average infection rate reported in literature is 10% (range 0–25%).

TABLE 1. Major findings and conclusions in the literature on silver-coated megaendoprostheses\*

Author, Reference	Journal, Year	Study Design	Patients (n)	Results	Conclusion
Gosheger et al. [16] Silver-coated megaendoprostheses in a rabbit model: analysis of infection rate and toxicological side effects	Biomaterials 2004	Animal trial	30 (silver n = 15, titanium n = 15)	The silver group showed significantly ( $p < 0.05$ ) lower infection rates (7% vs. 47%) in comparison with the titanium group after artificial contamination with <i>S. aureus</i>	The new silver-coated MUTARS megaprosthesis resulted in reduced infection rates in an animal trial
Hardes et al. [27] Lack of toxicological side effects in silver-coated megaprostheses in humans	Biomaterials 2007	Prospective	20	No sign of toxic side effect after implantation of silver-coated megaprostheses. The silver levels in blood were considered non-toxic. No changes in liver or kidney function	Silver coatings on megaprostheses show no local or systemic side effects
Hardes et al. [9] Reduction of periprosthetic infection with silver-coated megaprostheses in patients with bone sarcoma	Journal of Surgical Oncology 2010	Prospective (silver group); retrospective (titanium group)	125 (silver n = 51, titanium n = 74)	The infection rate was substantially, but not significantly, reduced from 17.6% in the titanium group to 5.9% in the silver group. Included were patients with a proximal femur or proximal tibia replacement	Using silver-coated prostheses reduced the infection rate over the medium term
Glehr et al. [28] Argyria following the use of silver-coated megaprostheses: no association between development of local argyria and elevated silver levels	Bone and Joint Journal 2013	Retrospective	32	Asymptomatic local argyria in 23% of patients with silver-coated megaprostheses. No systemic toxicity due to silver	However, the majority of the patients received silver-coated prostheses in revision, so that due to a negative pH value, increased release of Ag <sup>+</sup> ions may be suspected
Wafa et al. [31] Retrospective evaluation of the incidence of early periprosthetic infection with silver-treated endoprostheses in high-risk patients: case-control study	Bone and Joint Journal 2015	Retrospective	170 (silver n = 85, titanium n = 85)	This retrospective study showed a postoperative infection rate of 11.8% in the group with silver-coated prostheses vs. 22.4% in the group with uncoated prostheses ( $p = 0.033$ )	Silver-coated implants showed a reduced reinfection rate after PJI in two-stage revisions (success rates of 85% in silver group compared to 57.1% in uncoated group, $p = 0.05$ )
Politano et al. [20] Use of silver prevention and treatment of infections: silver review	Surgical Infections 2013	Review	-	Benefits of silver-coated orthopaedic prostheses are still unproved	
Wilding et al. [32] Can a silver-coated arthrodesis implant provide a viable alternative to above-knee amputation in the unsalvageable, infected total knee arthroplasty?	Journal of Arthroplasty 2016	Retrospective	8	With a mean follow-up period of 16 months (5-35 months), only one patient had recurrent infection, but prosthesis-preserving treatment was possible	The silver-coated arthrodesis is a good alternative to amputation, particularly in infected knee prostheses

\*Adapted from Schmidt-Braekling T, Streitbuenger A, Gosheger G, Boettner F, Nottrott M, Ahrens H, et al. Silver-coated megaprostheses: review of the literature. *Eur J Orthop Surg Traumatol.* 2017;27(4):483-489.

Silver coating of prosthesis is one of the methods studied so far. A number of retrospective studies have reported a decrease in the infection rate following use of silver-coated endoprosthesis. However, evidence from prospective and randomized trials is lacking [1]. See Table 1.

The Kanazawa group developed an iodine coating and published their results for the first time in 2012. In their study, 222 patients received iodine-coated implants of which 64 had active infection [2]. Their results suggest an even greater efficacy in prevention of infection as compared to silver coating interval and even eradication of infection in cases with active infection. Subsequent reporting by the same group in 2014 has also shown

greater efficacy of iodine-treated implants in patients with trauma, bone loss due to infections and tumor resection as well as revision setting with previously infected implants [3].

## REFERENCES

- [1] Schmidt-Braekling T, Streitbueger A, Gosheger G, Boettner F, Nottrott M, Ahrens H, et al. Silver-coated megaprotheses: review of the literature. *Eur J Orthop Surg Traumatol.* 2017;27(4):483-489. doi:10.1007/s00590-017-1933-9.
- [2] Tsuchiya H, Shirai T, Nishida H, Murakami H, Kabata T, Yamamoto N, et al. Innovative antimicrobial coating of titanium implants with iodine. *J Orthop Sci.* 2012;17:595-604. doi:10.1007/s00776-012-0247-3.
- [3] Shirai T, Tsuchiya H, Nishida H, Yamamoto N, Watanabe K, Nakase J, et al. Antimicrobial megaprotheses supported with iodine. *J Biomater Appl.* 2014;29:617-623. doi:10.1177/0885328214539365.



**Authors:** Mitchell Schwaber, Yaakov Dickstein, Elizabeth Temkin

## QUESTION 8: What is the most optimal local antimicrobial delivery strategy during limb salvage: antibiotic cement, silver-coated implant, iodine-coated implant, topical vancomycin powder, injection of antibiotics via drain tubing or other?

**RECOMMENDATION:** Unknown. No direct comparison has been made of different antimicrobial delivery strategies in oncological patients undergoing limb salvage procedures.

**LEVEL OF EVIDENCE:** Limited

**DELEGATE VOTE:** Agree: 100%, Disagree: 0%, Abstain: 0% (Unanimous, Strongest Consensus)

## RATIONALE

Surgical excision of primary malignant tumors and metastases of the bone frequently leads to large skeletal defects. While once amputation was typically the only solution, the introduction of megaprotheses and later modular megaprotheses has led to limb salvage becoming the standard of care [1]. Despite falling rates of mechanical failure, the risk of periprosthetic infection remains high in comparison with conventional arthroplasty [2]. Treatment of periprosthetic infections often requires surgical intervention and prolonged antibiotic therapy [3]. Ongoing efforts directed at finding an effective means of infection prophylaxis have been examined exclusively in small observational studies without direct comparison between methods, thus limiting their conclusions.

Published studies appear to support the use of silver-coated implants. Data exist for limb salvage in sites including the hip, proximal and distal femur, pelvis, proximal and distal tibia, humerus and radius [4-10]. Six cohort studies, all but one retrospective, compared oncological patients who received silver-coated implants with non-coated (mostly titanium) implants [4-8,10]. The results across the studies were uniform with fewer patients who received silver-coated implants developing periprosthetic infections than the patients who received non-coated prostheses.

Weak evidence from a single retrospective cohort study indicates that alloy-type megaprosthesis may influence the risk of subsequent infection [11]. Significantly more patients who received a cobalt-chrome prosthesis developed infection than patients who received titanium prostheses.

Very weak evidence exists suggesting that iodine-coated megaprotheses may reduce risk of periprosthetic infection [12]. Similarly, there are limited data supporting the use of iodine-coated hardware in patients undergoing reconstruction [13].

Despite the body of evidence on antibiotic-impregnated cement in arthroplasty, only one case series examined its effects specifically in orthopaedic oncology patients who underwent total knee prostheses [14].

## REFERENCES

- [1] Gkavardina A, Tsagozis P. The use of megaprotheses for reconstruction of large skeletal defects in the extremities: a critical review. *Open Orthop J.* 2014;8:384-389. doi:10.2174/1874325001408010384.
- [2] Racano A, Pazonis T, Farrokhyar F, Dehesi B, Ghert M. High infection rate outcomes in long-bone tumor surgery with endoprosthetic reconstruction in adults: a systematic review. *Clin Orthop Relat Res.* 2013;471:2017-2027. doi:10.1007/s11999-013-2842-9.
- [3] Osmon DR, Berbari EF, Berendt AR, Lew D, Zimmerli W, Steckelberg JM, et al. Diagnosis and management of prosthetic joint infection: clinical practice guidelines by the Infectious Diseases Society of America. *Clin Infect Dis.* 2013;56:e1-e25. doi:10.1093/cid/cis803.
- [4] Donati F, Di Giacomo G, Ziranu A, Spinelli S, Perisano C, Rosa MA, et al. Silver coated prosthesis in oncological limb salvage surgery reduce the infection rate. *J Biol Regul Homeost Agents.* 2015;29:149-155.
- [5] Donati F, Di Giacomo G, D'Adamio S, Ziranu A, Careri S, Rosa M, et al. Silver-coated hip megaprosthesis in oncological limb salvage surgery. *Biomed Res Int.* 2016;2016:9079041. doi:10.1155/2016/9079041.
- [6] Harges J, von Eiff C, Streitbueger A, Balke M, Budny T, Henrichs MP, et al. Reduction of periprosthetic infection with silver-coated megaprotheses in patients with bone sarcoma. *J Surg Oncol.* 2010;101:389-395. doi:10.1002/jso.21498.
- [7] Harges J, Henrichs MP, Hauschild G, Nottrott M, Guder W, Streitbueger A. Silver-coated megaprosthesis of the proximal tibia in patients with sarcoma. *J Arthroplasty.* 2017;32:2208-2213. doi:10.1016/j.arth.2017.02.054.
- [8] Piccioli A, Donati F, Giacomo GD, Ziranu A, Careri S, Spinelli MS, et al. Infective complications in tumour endoprotheses implanted after pathological fracture of the limbs. *Injury.* 2016;47 Suppl 4:S22-S28. doi:10.1016/j.injury.2016.07.054.
- [9] Schmolders J, Koob S, Schepers P, Pennekamp PH, Gravius S, Wirtz DC, et al. Lower limb reconstruction in tumor patients using modular silver-coated megaprotheses with regard to perimegaprosthesis joint infection: a case

- series, including 100 patients and review of the literature. *Arch Orthop Trauma Surg.* 2017;137:149–153. doi:10.1007/s00402-016-2584-8.
- [10] Wafa H, Grimer RJ, Reddy K, Jeys L, Abudu A, Carter SR, et al. Retrospective evaluation of the incidence of early periprosthetic infection with silver-treated endoprostheses in high-risk patients: case-control study. *Bone Joint J.* 2015;97-B:252–257. doi:10.1302/0301-620X.97B2.34554.
- [11] Gosheger G, Goetze C, Harges J, Joosten U, Winkelmann W, von Eiff C. The influence of the alloy of megaprotheses on infection rate. *J Arthroplasty.* 2008;23:916–920. doi:10.1016/j.arth.2007.06.015.
- [12] Shirai T, Tsuchiya H, Nishida H, Yamamoto N, Watanabe K, Nakase J, et al. Antimicrobial megaprotheses supported with iodine. *J Biomater Appl.* 2014;29:617–623. doi:10.1177/0885328214539365.
- [13] Shirai T, Tsuchiya H, Terauchi R, Tsuchida S, Mizoshiri N, Igarashi K, et al. The outcomes of reconstruction using frozen autograft combined with iodine-coated implants for malignant bone tumors: compared with non-coated implants. *Jpn J Clin Oncol.* 2016;46:735–740. doi:10.1093/jjco/hyw065.
- [14] Langlais F, Belot N, Ropars M, Lambotte JC, Thomazeau H. The long-term results of press-fit cemented stems in total knee prostheses. *J Bone Joint Surg Br.* 2006;88:1022–1026. doi:10.1302/0301-620X.88B8.17722.





## TREATMENT

## 2.1. TREATMENT: IRRIGATION AND DEBRIDEMENT

**Authors:** Oscar Ares, John Abraham, John Strony, Keenan Sobol, Ignacio Moya, Andrea Sallent

### QUESTION 1: How many irrigation and debridements (I&Ds) of an infected oncologic endoprosthesis are reasonable before consideration should be given to resection arthroplasty?

**RECOMMENDATION:** Decision to repeat irrigation and debridement and retention of an infected endoprosthesis (DAIR) should be made based on comorbidities of the host, virulence of the organism, complexity of the reconstruction and status of the soft tissues. We believe DAIR performed more than two or three times is unlikely to be successful.

**LEVEL OF EVIDENCE:** Consensus

**DELEGATE VOTE:** Agree: 100%, Disagree: 0%, Abstain: 0% (Unanimous, Strongest Consensus)

#### RATIONALE

The utilization of musculoskeletal tumor surgery has increased through the years thanks to the increase in therapeutic alternatives. One of these alternatives is resection of the tumor and implantation of a tumor endoprosthesis. These surgeries are complex, long and aggressive for the surrounding tissues. There are many possible complications following these procedures, of which periprosthetic joint infection is one of the most feared.

Infection rates in primary musculoskeletal surgeries have been reported from over 5% to over 15% [1,2]. Several risk factors have been identified, including malignancy of the primary tumor, surgical time, previous surgery, the use of chemotherapy and/or radiotherapy, tumor affectation of the skin and skin necrosis [3]. Identification of these factors is crucial because the onset of infection increases the rate of morbidity, mortality, the number of subsequent procedures and amputation [4].

The optimal treatment for oncologic endoprosthesis infection is currently a matter of debate. Several authors have investigated the role of DAIR, including the number of attempts that should be made before undergoing more aggressive surgery.

Dhanoa et al. [5] reviewed 105 patients with oncologic endoprosthesis infections. In their experience, I&D could be performed when the case met the following criteria: acute onset infection (14–28 days), clear-cut diagnosis based on histopathology and microbiology, stable implant and susceptibility of the microorganism to an effective orally-available antimicrobial agent. With this method they reported a 42.8% rate of infection eradication. In those patients in which debridement failed, a two-stage revision surgery would be performed without trying a second debridement. A similar therapeutic strategy was demonstrated by Kapoor et al. [6]. Patients would undergo as much as one surgical debridement before switching to two-stage revision if the debridement had failed. Both authors agree that late prosthetic infections are associated with poor results when treated by lavage, debridement or prolonged antibiotics administration. Therefore, removal of the infected prosthesis either as one- or two-stage procedure, resection arthroplasty or an amputation becomes necessary. Funovics et al. [2] reported a 50% eradication rate after surgical debridement. In

their experience, when debridement alone failed, one-stage revision surgery was performed.

Not all authors view debridement as an inferior method in treating endoprosthetic infection, however. Allison et al. [7] treated 329 musculoskeletal tumors and reported a 13.9% overall infection. Although they did not clarify how patients were selected for each treatment method, they reported a 70% healing rate after single-stage irrigation and debridement with exchange of the modular component and varying degrees of suppressive antibiotics. That healing rate was superior to the one they achieved after revision, antibiotic spacer placement and subsequent reimplantation (62%). On the other hand, Jeys et al. [8] claim that I&D alone has a poor outcome in endoprosthetic infection. After treating 136 patients, they reported only a 6% eradication rate after debridement only. They also state that healing after resection arthroplasty was achieved in 50% of cases, but they do not specify the reason why patients were treated one way or another.

Not all authors believe that surgical debridement should be a step in management of oncologic endoprosthesis infection. Holtzer et al. [9] treated 18 patients with endoprosthetic infection. They considered debridement a poor option and thus performed one-stage revision surgeries in all cases. Infection was eliminated in 14/18 patients (77.78%). In a similar manner, Harges et al. [10] treated 30 patients and developed a therapeutic algorithm for oncologic endoprosthesis infection that did not include I&D. They believed that one-stage revision surgery should be performed whenever possible. If one-stage revision is not possible, then two-stage revision should be performed. If two-stage revision is not possible, then arthrodesis should be performed. Finally, if arthrodesis is not possible, then amputation should be performed. Out of 30 patients, 19 (63.33%) were cured with a one- or two-stage revision. Of the remaining 11, amputation was performed in 6/30 (20%).

In conclusion, it is unclear if I&D serves as a good alternative for the treatment of an infected endoprosthesis. In addition, the number of attempts that should be made towards I&D before revision surgery or amputation is uncertain. It seems that for acute infections with an antibiotic-sensitive microorganism, debridement

may be a good first step in the treatment algorithm, but failure rates are high, and no more than two surgical debridements should be attempted before considering a revision surgery in order to achieve infection eradication.

## REFERENCES

- [1] Morii T, Morioka H, Ueda T, Araki N, Hashimoto N, Kawai A, et al. Deep infection in tumor endoprosthesis around the knee: a multi-institutional study by the Japanese musculoskeletal oncology group. *BMC Musculoskelet Disord.* 2013;14:51. doi:10.1186/1471-2474-14-51.
- [2] Funovics PT, Hipfl C, Hofstaetter JG, Puchner S, Kotz RI, Dominkus M. Management of septic complications following modular endoprosthetic reconstruction of the proximal femur. *Int Orthop.* 2011;35:1437-1444. doi:10.1007/s00264-010-1054-0.
- [3] Morii T, Yabe H, Morioka H, Beppu Y, Chuman H, Kawai A, et al. Postoperative deep infection in tumor endoprosthesis reconstruction around the knee. *J Orthop Sci.* 2010;15:331-339. doi:10.1007/s00776-010-1467-z.
- [4] Morii T, Morioka H, Ueda T, Araki N, Hashimoto N, Kawai A, et al. Functional analysis of cases of tumor endoprostheses with deep infection around the knee: a multi institutional study by the Japanese Musculoskeletal Oncology Group (JMOG). *J Orthop Sci.* 2013;18:605-12. doi:10.1007/s00776-013-0389-y.
- [5] Dhanoa A, Ajit Singh V, Elbahri H. Deep infections after endoprosthetic replacement operations in orthopedic oncology patients. *Surg Infect (Larchmt).* 2015;16:323-332. doi:10.1089/sur.2014.049.
- [6] Kapoor SK, Thiyam R. Management of infection following reconstruction in bone tumors. *J Clin Orthop Trauma.* 2015;6:244-251. doi:10.1016/j.jcot.2015.04.005.
- [7] Allison D, Huang E, Ahlmann E, Carney S, Wang L, Menendez L. Peri-prosthetic infection in the orthopedic tumor patient. *Reconstr Rev.* 2014;4.
- [8] Jeys LM, Grimer RJ, Carter SR, Tillman RM. Periprosthetic infection in patients treated for an orthopaedic oncological condition. *J Bone Joint Surg Am.* 2005;87:842-849. doi:10.2106/JBJS.C.01222.
- [9] Holzer G, Windhager R, Kotz R. One-stage revision surgery for infected megaprotheses. *J Bone Joint Surg Br.* 1997;79:31-35.
- [10] Harges J, Gebert C, Schwappach A, Ahrens H, Streitburger A, Winkelmann W, et al. Characteristics and outcome of infections associated with tumor endoprostheses. *Arch Orthop Trauma Surg.* 2006;126:289-296. doi:10.1007/s00402-005-0009-1.



**Authors:** João Paulo Fonseca de Freitas, Faiz Shivji, Scot A. Brown, Diogo Moura, Isabel Ferreira, Michael J. Petrie, John Strony

## QUESTION 2: How should acute reinfection of an oncologic endoprosthesis be treated?

**RECOMMENDATION:** Acute reinfections in patients with oncologic endoprostheses demand treatment by surgical methods because the long-term administration of antibiotics alone is not sufficient. The most appropriate treatment modality for acute re-infection is debridement, antibiotics and implant retention (DAIR) with exchange of components.

**LEVEL OF EVIDENCE:** Consensus

**DELEGATE VOTE:** Agree: 100%, Disagree: 0%, Abstain: 0% (Unanimous, Strongest Consensus)

## RATIONALE

Oncology patients represent a high-risk subset of the population. The implantation of endoprostheses in this cohort of patients leads to an increased risk of infection due to their immunocompromised state, previous radiotherapy, poor soft tissues, poor nutritional status or significant comorbidities [1].

Many options have been proposed to prevent infections of an endoprosthesis. However, there are no current appropriate guidelines or recommendations to guide optimal management of an acute endoprosthetic reinfection. There is a paucity of literature regarding the results of these different procedures, though it has been shown that irrigation, debridement and prolonged antibiotic administration have the poorest results in treating late prosthetic infections [2]. Therefore, removal of the infected prosthesis either as one- or two-stage procedure or an amputation may be necessary [2].

Allison et al. reviewed 329 patients who had undergone arthroplasty surgery for definitive oncological treatment [3]. Of those that became infected and were treated with irrigation and debridement without component exchange, there was a 42% success rate at eradicating infection. With single stage exchange, this increased to 70%. Two-stage revision led to a 62% success rate. Conversely, previous literature has associated two-stage revisions as having a higher success rate when compared with one-stage [4-6]. As one would expect, amputation has been shown to carry the highest rate of infection eradication. The risk of amputation due to an infected endoprosthesis has been reported to be between 23.5% and 87% [4,7,8].

Periprosthetic infection can lead to a poor functional outcome as well as an increased morbidity and mortality. Management of infections after reconstructive surgery for bone tumors is a challenge, requiring careful planning, consideration of the patient's prognosis and a potentially aggressive surgical approach.

## REFERENCES

- [1] Racano A, Pazonis T, Farrokhyar F, Deheshi B, Ghert M. High infection rate outcomes in long-bone tumor surgery with endoprosthetic reconstruction in adults: a systematic review. *Clin Orthop Relat Res.* 2013;471:2017-2027. doi:10.1007/s11999-013-2842-9.
- [2] Kapoor SK, Thiyam R. Management of infection following reconstruction in bone tumors. *J Clin Orthop Trauma.* 2015;6:244-251. doi:10.1016/j.jcot.2015.04.005.
- [3] Allison D, Huang E, Ahlmann E, Carney S, Wang L, Menendez L. Peri-prosthetic infection in the orthopedic tumor patient. *Reconstr Rev.* 2014;4.
- [4] Grimer RJ, Belthur M, Chandrasekar C, Carter SR, Tillman RM. Two-stage revision for infected endoprostheses used in tumor surgery. *Clin Orthop Relat Res.* 2002:193-203.
- [5] Harges J, Ahrens H, Gosheger G, Nottrott M, Dieckmann R, Henrichs M-P, et al. [Management of complications in megaprotheses]. *Unfallchirurg.* 2014;117:607-613. doi:10.1007/s00113-013-2477-z.
- [6] Eralp L, Ozger H, Kocaoglu M. Treatment strategies for infected megaprosthesis. *Orthop Proc.* 2009;91-B301. doi:10.1302/0301-620X.91BSUPP-II.0910301a.
- [7] Jeys LM, Grimer RJ, Carter SR, Tillman RM. Periprosthetic infection in patients treated for an orthopaedic oncological condition. *J Bone Joint Surg Am.* 2005;87:842-849. doi:10.2106/JBJS.C.01222.
- [8] Shehadeh A, Noveau J, Malawer M, Henshaw R. Late complications and survival of endoprosthetic reconstruction after resection of bone tumors. *Clin Orthop Relat Res.* 2010;468:2885-2895. doi:10.1007/s11999-010-1454-x.





Authors: Paul Jutte, Hesham Abdelbary, Claudia Löwik

**QUESTION 3:** Is irrigation and debridement and exchange of modular parts a viable option for treatment of acute periprosthetic joint infection (PJI) involving oncologic endoprosthesis? If so, what are the indications?

**RECOMMENDATION:** Yes. Irrigation and debridement with retention of prosthesis (DAIR) is a viable option for management of patients with infected endoprosthesis. The procedure may be offered to patients with superficial early infection (< 3 months), short duration of symptoms (< 3 weeks), well-fixed implants and well-characterized organism demonstrating a highly susceptible pathogen.

**LEVEL OF EVIDENCE:** Moderate

**DELEGATE VOTE:** Agree: 100%, Disagree: 0%, Abstain: 0% (Unanimous, Strongest Consensus)

### RATIONALE

Surgical reconstruction using an endoprosthesis after tumor resection is frequently associated with deep surgical site infection that leads to PJI. The prevalence of PJI associated with oncologic endoprosthesis is 7-28% compared to only 1-2% in primary joint replacements. Cancer patients are at a higher risk for developing PJI after receiving an endoprosthesis due to numerous risk factors, which lead to local and systemic immunodeficiency. These risk factors include chemotherapy, radiotherapy, prolonged surgical time, increased bleeding, larger implant surface area and compromised soft tissue envelope.

In case of an infected oncologic endoprosthesis, debridement, antibiotics and implant retention (DAIR) can be performed, especially in early acute infections (< 3 months). If

DAIR fails to eradicate the infection, a two-stage revision is necessary. In the literature, two-stage revision is generally reported as a good surgical approach for infection control with a reported success rate of 63-100% [1-6]. Eradication of infection is generally worse after a single-stage revision and, of course, better after an amputation [4,7-9].

In order to optimize the treatment of patients with an infected oncologic endoprosthesis we performed a literature search to assess factors associated with successful eradication of the infection after DAIR. Although various studies assessed infection of oncologic endoprostheses, only few specifically evaluated the efficacy of DAIR [2,3]. We assessed the literature for indications as well as factors that influenced the treatment outcomes of DAIR. Due to the lack

**TABLE 1.** PubMed relevant search terms

Database	Search Terms	Total
PubMed English Until 01 Feb 2018	PICO 1a: (((((infection) AND ((prosthetic joint OR endoprosthesis* OR arthroplast* OR megaprosthesis* OR tumourprosthesis* OR tumorprosthesis*))) AND ((oncolog* OR tumour OR tumor)))) AND ((two stage OR revision))) AND ((antibiotic* OR antimicrobial* OR holiday period))	39
	PICO 1b: (((((prosthetic joint OR endoprosthesis* OR arthroplast* OR megaprosthesis* OR tumourprosthesis* OR tumorprosthesis*))) AND ((oncolog* OR tumour OR tumor))) AND ((two stage OR revision))) AND ((chemo OR chemotherapy))	67
	PICO 1c: (((((prosthetic joint OR endoprosthesis* OR arthroplast* OR megaprosthesis* OR tumourprosthesis* OR tumorprosthesis*))) AND ((oncolog* OR tumour OR tumor))) AND ((two stage OR revision))) AND radiotherapy	23
	PICO 1d: (((((prosthetic joint OR endoprosthesis* OR arthroplast* OR megaprosthesis* OR tumourprosthesis* OR tumorprosthesis*))) AND ((oncolog* OR tumour OR tumor))) AND ((two stage OR revision))) AND ((micro-organism OR bacter* OR culture))	44
	PICO 1e: (((((prosthetic joint OR endoprosthesis* OR arthroplast* OR megaprosthesis* OR tumourprosthesis* OR tumorprosthesis*))) AND ((oncolog* OR tumour OR tumor))) AND ((two stage OR revision))) AND spacer	19
	PICO 1f: (((((((prosthetic joint OR endoprosthesis* OR arthroplast* OR megaprosthesis* OR tumourprosthesis* OR tumorprosthesis*))) AND ((oncolog* OR tumour OR tumor))) AND ((two stage OR revision))) AND infection)) AND silver	10
	PICO 2: (((((prosthetic joint OR endoprosthesis* OR arthroplast* OR megaprosthesis* OR tumourprosthesis* OR tumorprosthesis*))) AND ((oncolog* OR tumour OR tumor))) AND ((DAIR OR debridement OR irrigation OR washout))	74

TABLE 2. Evidence table

Author and Year	Study Type	Patients	Procedures	Follow-up	Major Outcomes
Bus 2017 [17]	Retrospective cohort 2008–2014	N = 47 LUMIC reconstruction for pelvic tumor	* 69% DAIR * 31% implant removal	3-9 years	* 28% had infection. * 69% were successfully treated with DAIR (2). * 31% needed implant removal. Two had amputation, one rotationplasty and one LUMIC prosthesis. * More blood loss was associated with a higher risk of infection; other factors were not associated.
Chambers 1962 [18]	Narrative review	X	X	X	* Article on the bactericidal effects of silver (1f).
Dhanoa 2015 [1]	Retrospective cohort 2007–2011	N = 105 Endoprosthesis reconstruction for tumor	* 54% DAIR * 46% 2-SR	32 months	* 12.4% infection at 0-63 months. * Higher risk after additional procedures (13x), comorbidity, proximal tibia endoprosthesis, pelvic endoprosthesis and preoperative hospitalization >48 hour. Lower risk with distal femoral prostheses. * 80% of infections had operations >2.5h, compared to 16.3% in non-infections. * 38% Staph aureus, 31% CNS, 23% Klebsiella pneumoniae, 23% Pseudomonas aeruginosa. 38.5% had polymicrobial infection (1d). * 80% of 2-SR were successful; 1 patient had antibiotic suppression. * 43% of DAIR were successful; 2 patients had antibiotics; 2 patients had amputation (2).
Donati 2016 [19]	Retrospective case-control 2005–2016	N = 68 Megaprosthesis reconstruction for proximal femur tumors	X	47 months (12-114 months)	* Overall infection rate 11.8% at mean 25 months: silver 7.9%, control 16.7% (1f). * In late infection, explanted megaprosthesis had important degradation of the coating surface (1f). * No differences in functional scores between silver and control (1f). * No local or general signs of toxicity (1f).
Felden 2015 [20]	Prospective cohort 1995–2011	N = 45 Pelvic irradiation before cemented THA	X	51 months (17-137 months)	* Patient survival was 71% at 2y, 52% at 5y and 41% at 10y. * The cumulative probability of revision was 2.2% at 1y, 2.2% at 2y, 8.1% at 5y and 20.2% at 10y. * 6% underwent revision for infection, 1 treated with 2-SR, 2 treated with 1-SR (all successful).
Flint 2007 [2]	Prospective cohort 1989–2004	N = 15 Infection after un cemented Kotz prostheses for bone sarcoma	2-SR	42 months (3-150 months)	* Prosthetic infection occurred at mean 28 months (1-132 months). * 75% CNS, 33% Staph aureus, 8% Pseudomonas aeruginosa, 8% E. coli, 8% Streptococcus viridans (1d). * 73% had second-stage revision: 27% had amputation, 73% with infection control after second-stage. * 60% success with retention of diaphyseal stems; 40% success with removal of anchorage pieces. * No relation between success and anatomical location or infecting organism (1d). * 66% of failures had previous radiation (1c). * In case of infection within 6 months 86% of 2-SR was successful, after 6 months only 25%.

TABLE 2. Evidence table (Cont.)

Author and Year	Study Type	Patients	Procedures	Follow-up	Major Outcomes
Funovics 2011 [7]	Retrospective cohort 1982–2008	N = 166 Endoprosthetic reconstruction for tumor	* 83% 1-SR * 8% muscle flap * 8% deceased	47 months (0–365 months)	* Survival rate without infection was 95.9% at 1y, 89.2% at 5y, 89.2% at 10y and 77.8% at 20y. * 7.2% had infection at mean 39 months (0–167 months). * 30% CNS, 30% Staph epidermidis. Polymicrobial infection in 30.8% (1d). * Higher rate of infection in primary tumors, cemented prostheses, pelvic reconstruction, additional operations or radiotherapy (1c). * 63% infection control by 1-SR, 13% additional 1-SR, 25% additional 2-SR.
Gitelis 2008 [21]	No full text	X	X	X	X
Grimer 2002 [3]	Prospective cohort 1989–1998	N = 34 Infection after endoprostheses for sarcoma	2-SR	6–116 months	* Obvious causes of infection included lengthening or rebushing procedures, infected ingrown toenail, chest infection, infected burn blister, infected Hickman catheter and neutropenic septicemia. * 53% CNS, 32% Staph aureus, 6% streptococci, 3% Enterobacter and 3% Corynebacterium (1d). * 70% had infection control after 2-SR. 6% needed amputation within 6 months. 6% needed additional 2-SR (1 successful, 1 not). 18% had late infections with various treatments. * Overall success rate for controlling infection was 94% at 6 months, 91% at 1 year, 74% at 5 years and 65% at 10 years. * Reinfection occurred in all 3 patients with previous radiotherapy (1c). * Functional outcome after successful infection control was mean 77% MSTs (47–100%).
Hardes 2006 [8]	Retrospective cohort 1992–2003	N = 30 Infection after MUTARS tumor endoprostheses for sarcoma	* 3.3% antibiotics * 10% 1-SR * 80% 2-SR	32 months (3–128 months)	* Infection occurred at mean time 16 months (1–70 months). * 62% CNS, 21% Staph aureus, 14% Enterococcus species. 21% had polymicrobial infections (1d). * 1-SR was successful in 33%, 2-SR in 63% * 33% of 2-SR failures needed amputation, 33% rotationarthroplasty, 11% arthrodesis, 22% retained the spacer (1 died after 4 months, 1 had satisfactory function). * 8.3% needed a change of spacer (1f). * The most important risk factor for failed limb salvage was poor soft-tissue. * Chemotherapy, time of occurrence of infection, virulence and type of infection had no influence (1b). * A mean of 2.6 revision operations per patients, mean duration of hospital stay 68 days.

TABLE 2. Evidence table (Cont.)

Author and Year	Study Type	Patients	Procedures	Follow-up	Major Outcomes
Hardes 2007 [22]	Prospective cohort 2002–2004	N = 20 Silver-coated MUTARS tumor endoprosthesis for metastasis	X	19 months (2–32 months)	<ul style="list-style-type: none"> <li>* No patients had signs of local or systemic argyrosis (if).</li> <li>* The mean serum silver concentration was 0.37 ppb preoperatively, 2.80 ppb 2 week postoperatively. Between 2 and 24 months silver concentration varied from 1.93–12.98 ppb (if).</li> <li>* 10 patients showed decreased glomerular filtration rates (if).</li> <li>* The silver-coating was intact in all patients. Histologic examination showed no signs of chronic inflammation, granulomas or necrotic tissue (if).</li> </ul>
Hardes 2010 [23]	Prospective case-control 2005–2009	N = 51 (74 control) Silver-coated replacement for bone or soft-tissue tumors	Various	19 months (3–63 months)	<ul style="list-style-type: none"> <li>* 5.9% with silver had infections compared to 17.6% with titanium prostheses, at mean 11 months (if).</li> <li>* Patients with infection had longer operating time (305 vs. 228 minutes).</li> <li>* 38.5% with titanium prostheses had amputation or rotationplasty for infection, 0% in silver group (if).</li> <li>* In the silver group 2 were treated with antibiotics alone, 1 had minor revision (one-stage without removal of the stem), all were successful (if).</li> </ul>
Henderson 2011 [24]	Retrospective cohort 1974–2008	N = 2,174 Limb preservation with metallic endoprosthesis for tumor	X	X	<ul style="list-style-type: none"> <li>* 24.5% were considered failures, of which 12% had soft tissue problems, 19% aseptic loosening, 17% fracture, 17% tumor progression, 34% infection.</li> <li>* Infection occurred more often in hinged prostheses than in polyaxial prostheses (<math>p &lt; 0.05</math>).</li> <li>* Failure incidence decreased over time. The mean time to failure was 47 months.</li> <li>* Literature review of 4359 patients with 29% failures.</li> </ul>
Hollinger 1996 [25]	No full text	X	X	X	
Hsu 1999 [26]	Prospective cohort 1975–1986	N = 38 Limb salvage for tumors needing revision surgery	<ul style="list-style-type: none"> <li>* 50% revision</li> <li>* 32% amputation</li> <li>* 10% arthrodesis</li> <li>* 8% miscellaneous</li> </ul>	51 months	<ul style="list-style-type: none"> <li>* Indications for reoperation were aseptic loosening (34%), instability (13%), infection (13%), tumor recurrence (13%), fracture (11%) and miscellaneous (16%).</li> <li>* 16% died after revision at a mean of 40 months after revision.</li> <li>* After revision functional results were excellent (12.5%), good (81.3%) or fair (6.25%).</li> <li>* 63% had radiolucent zones immediately after revision. 25% of these developed progressive changes that had an effect on limb function.</li> <li>* Patients with revision had higher survival rates and longer disease-free intervals than patients with amputation (<math>p &lt; 0.01</math>).</li> <li>* Overall 18.4% had complications: 5.3% aseptic loosening, 5.3% infection, 2.6% non-union, 2.6% local recurrence and 2.6% instability.</li> </ul>
Jacobs 1995 [27]	Retrospective cohort 1983–1991	N = 9 Uncemented THA with previous pelvic irradiation	X	37 months (17–78 months)	<ul style="list-style-type: none"> <li>* 4/9 radiographic and clinical migrations, 2/4 had revision, of which 1 needed Girdlestone after revision (1c).</li> </ul>

TABLE 2. Evidence table (Cont.)

Author and Year	Study Type	Patients	Procedures	Follow-up	Major Outcomes
Jays 2003 [28]	Retrospective cohort 1966–2001	N = 1,261 Endoprosthetic replacement	Amputation	5.2 years	<ul style="list-style-type: none"> <li>* Overall patient survival was 60% at 5 years, 54% at 10 years and 40% at 20 years.</li> <li>* Overall limb survival without amputation was excellent with 91% at 20 years.</li> <li>* Overall risk of amputation was 8.9% of which the reasons were local recurrence (63%), infection (34%), mechanical failure (2%) and persistent pain (1%).</li> <li>* Risk of amputation after infection was 19% compared to 36% for local recurrence.</li> <li>* Time to amputation was a mean of 32 months for infection.</li> </ul>
Jays 2005 [4]	Retrospective cohort 1966–2001	N = 1,240 Prosthetic replacement for bone tumor	<ul style="list-style-type: none"> <li>* 43% 2-SR</li> <li>* 32% amputation</li> <li>* 24% 1-SR</li> <li>* 2% Girdlestone</li> </ul>	5.8 years (0.3-34 years)	<ul style="list-style-type: none"> <li>* 11% had infection from 1996-2001 3.7%, 14% from 1966-1996.</li> <li>* 88% presented within 2 years after the last surgical procedure.</li> <li>* 48% had Staphylococcus epidermidis, 26% had polymicrobial infection (1d).</li> <li>* Polymicrobial infections did not reduce the rate of successful treatment of infection (1d).</li> <li>* Success rates: amputation 98%, 2-SR 72%, Girdlestone 50%, 1-SR 42%.</li> </ul>
Jays 2007 [29]	Retrospective cohort 1966–2001	N = 412 Endoprosthetic reconstruction for osteosarcoma	X	6.7 years (0-20 years)	<ul style="list-style-type: none"> <li>* 10% had deep infection at mean time 4.6 months.</li> <li>* 52% had Staph epidermidis, 29% Staph aureus (1d).</li> <li>* There was better survival in patients infected with Staphylococcus (10y survival 92%, mixed organisms 79%, no infection 62.2%, Streptococcus 50%) (1d)</li> <li>* There was no evidence that patients with infections had more effective chemotherapy (1b)</li> <li>* There were more infections after radiotherapy (p=0.02) (1c)</li> </ul>
Jays 2007 [30]	Retrospective cohort 1966–2001	N = 1,254 63 radiotherapy Endoprosthetic replacement for bone tumor	X	5.8 years (0.3-33 years)	<ul style="list-style-type: none"> <li>* Mean postoperative MSTS function score was lower after radiotherapy (64% vs. 81.3%) (1c)</li> <li>* Risk of infection without radiotherapy 9.8%, preoperative radiotherapy 20.7%, postoperative radiotherapy 35.3% (1c).</li> <li>* Risk of amputation without radiotherapy 7.8%, preoperative radiotherapy 17.2%, postoperative radiotherapy 14.7% (1c).</li> <li>* 10y survival was worse after radiotherapy (29%) than without radiotherapy (58%) (1c).</li> </ul>
Jays 2009 [31]	No full text (chapter book)	X	X	X	
Kaminsky 2017 [32]	No full text	X	X	X	
Kim 2007 [33]	Prospective cohort 1997–2003	N = 51 Uncemented THA with irradiation of the pelvis for adenocarcinoma of the prostate	X	4.8 years (2-7.5 years)	<ul style="list-style-type: none"> <li>* 47% had radiation induced osteonecrosis of the femoral head (1c).</li> <li>* 6% had wound discharge, which healed without surgical treatment (1c).</li> <li>* 2% had deep infection, which required subsequent resection arthroplasty (successful) (1c).</li> </ul>

TABLE 2. Evidence table (Cont.)

Author and Year	Study Type	Patients	Procedures	Follow-up	Major Outcomes
Lansdown 2010 [34]	Narrative review	X	X	X	<ul style="list-style-type: none"> <li>* Paper about the mechanisms of absorption and metabolism of silver in the human body, presumed mechanisms of argyria and the elimination of silver-protein complexes in the bile and urine (1f).</li> <li>* Argyria and argyrosis are the principle effects associated with heavy deposition of insoluble silver precipitates in the dermis and cornea/conjunctiva. Argyria is not associated with pathological damage (1f).</li> </ul>
Lee 2002 [5]	Retrospective cohort 1985–1998	N = 145 18 infection  Tumor prosthesis for bone and soft tissue tumors	* 78% DAIR * 11% 2-SR * 11% 1-SR	44 months (5-136 months)	<ul style="list-style-type: none"> <li>* 12.4% had infection at mean 8 months (0.5-54 months).</li> <li>* 39% was successfully treated with DAIR or revision; 17% needed arthrodesis and 11% amputation (2).</li> <li>* 100% of 2-SR were successful, 0% of 1-SR were successful.</li> <li>* 33% with uncontrolled infection by DAIR and refused prosthesis removal had suppressive antibiotics.</li> <li>* The knee joint seemed to show poor outcome, but this was not statistically meaningful.</li> <li>* Infection control was poor in cases of cementless fixation (<math>p &lt; 0.01</math>).</li> <li>* Chemotherapy gave a higher risk of infection (18.7% vs. 5.6%) (1b).</li> <li>* Soft tissue defects (sinus, pus discharge, wound dehiscence) correlated with poor prognosis (<math>p &lt; 0.05</math>).</li> </ul>
Li 2011 [35]	Retrospective cohort 1993–2008	N = 53  Endoprosthetic reconstruction for sarcoma	DAIR	10 years	<ul style="list-style-type: none"> <li>* 1.9% had early infection, successfully treated with DAIR (2).</li> <li>* 5.7% had late infections, all treated with DAIR. One was successful, 2 needed revision (successful) (2).</li> <li>* 7.5% had wound complications requiring repeat surgery (debridement and closure) (2).</li> </ul>
Manoso 2006 [16]	Retrospective cohort 1990–2001	N = 11  Infected knee reconstruction after limb-salvage surgery for cancer treated with staged protocol	Staged reconstruction protocol	X	<ul style="list-style-type: none"> <li>* 82% had chronic infection, with a sinus tract in 45% at mean time 6 months (1-210 months).</li> <li>* 45% had failed DAIRs (2).</li> <li>* 55% had Staph aureus, 27% had Staph epidermidis. In 55%, a single organism caused the infection (1d).</li> <li>* 82% were immunocompromised with the administration of chemotherapy at the time of infection (1b).</li> <li>* All limbs were spared without amputation or flap loss. Overall cure rate was 91%.</li> <li>* Early complications were 2 peroneal palsies and 1 venous flap congestion requiring wound revision.</li> <li>* The mean functional outcome was 23/30 and mean knee range of motion 98 degrees.</li> </ul>
Massin 1995 [36]	Excluded	X	X	X	X

TABLE 2. Evidence table (Cont.)

Author and Year	Study Type	Patients	Procedures	Follow-up	Major Outcomes
Mavrogenis 2015 [37]	Retrospective cohort 1983–2010	N = 1,161 Megaprosthesis reconstruction after limb salvage surgery for sarcoma	* 83% 2-SR * 12% 1-SR * 5% amputation	Mean 9 years (3–20 years)	* 8.6% had infection at mean time 3.7y. * Most common isolates were Staph epidermidis (47%), Staph aureus (19%) and pseudomonas (6%) (1d). * Overall survival rate of megaprotheses was 88% at 10y and 84% at 20y. * Survival was higher for cementless reconstruction, not different for type of megaprosthesis, site of reconstruction or adjuvant therapy (1b).
Mavrogenis 2011 [38]	Narrative review	X	X	X	* DAIR may be effective in early infections, with short duration of symptoms, well-fixed implants and ideally with well-characterized microbiology demonstrating a highly susceptible pathogen (2). * Success in 2-SR 72–91%, 1-SR 42% and amputation 98–100%. * 2-SR is recommended for persistent infections, antibiotic-resistant pathogens or failed 1-SR. In well-fixed cementless modular prostheses anchorage stems can be retained. * Disadvantages of 2-SR are long hospitalization, increased bone loss, disuse osteoporosis, difficult revision operations and shortening of the affected limb. * Reimplantation should be delayed after completion of chemotherapy (1b). * An antibiotic-loaded cement spacer is essential in 2-SR; added antibiotics should be heatstable (1e). * Most surgeons administer systemic antibiotics 6 weeks, with reimplantation after > 2 months (1a).
McDonald 1990 [39]	Retrospective cohort 1970–1986	N = 304 271 malignant 33 benign Prosthesis or non-biological spacer in limb salvage surgery for primary bone tumors	X	2 years	* 11.8% had infection, 22% of these patients needed amputation. * Adjuvant and neo-adjuvant chemotherapy gave a higher risk of complications (32.8% and 55.4% vs 25.2%). Reconstruction with uncemented prostheses had fewest complications (1b).
Mittermayer 2002 [40]	Excluded	X	X	X	
Moriri 2010 [41]	Retrospective cohort 2000–2008	N = 82 Endoprosthetic reconstruction for knee tumors	X	52 months (9–105 months)	* 17% had infection at mean time 10.9 months. * 50% had Staph aureus, 30% Staph epidermidis and 10% Pseudomonas (1d). * Age, sex, tumor origin, comorbidities, operating time, blood loss, chemotherapy, clean air operating room, extracapsular resection, prosthesis type, number of postoperative antibiotics, posterior muscle flap were not risk factors for infection (1b). * Skin necrosis and surface infection were risk factors for infection.

TABLE 2. Evidence table (Cont.)

Author and Year	Study Type	Patients	Procedures	Follow-up	Major Outcomes
Morri 2013 [6]	Retrospective cohort 1995–2009	N = 388 Endoprosthetic reconstruction for knee tumors	* 45% debridement * 14% 2-SR * 10% amputation * 9% 1-SR * 7% soft tissue flap	66 months (5–213 months)	* 14.6% had infection at mean time 13 months. * 47% Staph aureus and 17.5% Staph epidermidis (1d). * Infections were controlled in 84.2% the others had an accepted fistula or suppressive antibiotics. * Patients with diabetes, bone metastasis, lack of gastrocnemius flap coverage and pus required more surgical interventions for infection control. * The most successful therapy was 2-SR (80% success). Therapies with prosthesis removal were more successful than other therapies.
Peel 2014 [9]	Retrospective cohort 1996–2010	N = 121 Tumor endoprostheses surgery	* 53% DAIR * 24% 2-SR * 12% 1-SR * 6% resection * 6% amputation	34 months (17–80 months)	* 14% had infection at median time 18 months * Parenteral antibiotics median 9 days (0–58), 82% received oral combination antibiotic therapy with rifampicin (365 days) (1a). * Success rates: DAIR 75%, 1-SR 100%, 2-SR 50%, resection 0%, amputation 100% (2). * The majority of treatment failures occurred in patients with multi-resistant organisms (1d).
Pilge 2012 [42]	No full text	X	X	X	X
Racano 2013 [43]	Systematic review 1990–2011	N = 4,838 in 48 level IV studies	X	X	* Pooled infection rate was 10% (0–25%). * Most common organisms were Staph aureus and Staph epidermidis (1d). * There is considerable variation in antibiotic regimens. 0–24 hour antibiotic prophylaxis had 13% infection, >24 hour prophylaxis had 8% infection (p<0.05) (1a).
Renard 2000 [44]	Prospective cohort 1975–1995	N = 77 Limb saving surgery (50) or ablative surgery (25) for sarcoma	X	97 months (28–271 months)	* 6% had deep infection, leading to amputation in 2/3 cases. * 4% had superficial infection successfully treated with DAIR and gentamicin beads (2).
Sherman 2008 [45]	Excluded	X	X	X	X
Shin 1999 [46]	Retrospective cohort 1970–1990	N = 52 41 malignant 11 benign Limb salvage surgery for musculoskeletal tumor	* 67% revision * 21% amputation * 8% arthrodesis * 2% fibular graft * 2% ORIF	12 years (37–296 months)	* 11.5% had infection. * Functional rating was 63%. Pain 69%, function 53%, emotional acceptance 72%, support 60%, walking ability 62%, gait 54%, hand positioning 66%, manual dexterity 94% and lifting ability 63%. * After revision 33% needed reoperation for complications: 58% aseptic loosening, 25% infection, 17% prosthetic failure and 8% patellar dislocation. * Survival after reoperation was 79% (5y) and 65% (10y).



TABLE 2. Evidence table (Cont.)

Author and Year	Study Type	Patients	Procedures	Follow-up	Major Outcomes
Sim 2007 [47]	Retrospective cohort 1996 – 2005	N = 50 Endoprosthetic reconstruction for knee tumors (GRMS)	3 washouts	24-5 months (2-124 months)	<ul style="list-style-type: none"> <li>* Patients with metastatic disease or pathological fractures did not have higher complication rates.</li> <li>* 12% had deep infection for which patients received multiple washouts and long-term antibiotics (2).</li> <li>* 1/6 had revision; 1/6 had amputation (2).</li> </ul>
Wafa 2015 [48]	Prospective case-control 2006–2011	N = 170 Reconstruction with silver-enhanced endoprostheses for several indications	X	12 months	<ul style="list-style-type: none"> <li>* 11.8% infection in silver group, 22.4% in control group (1f).</li> <li>* Higher incidence of Pseudomonas in the silver group (1d/1f).</li> <li>* 70% of infected prosthesis was successfully treated with DAIR, 31.6% in the control group (1f/2).</li> <li>* 15.3% required implant removal, amputation or antibiotic suppression, 3.5% in the silver group (1f).</li> <li>* 18.8% with adjuvant chemotherapy developed infection (1b).</li> <li>* 15% had relapse infection after 2-SR in the silver group, 42.9% in the control group (1f).</li> </ul>
Wirganowicz 1999 [49]	Prospective cohort 1980–1995	N = 64 Failed endoprostheses for neoplastic disease	<ul style="list-style-type: none"> <li>* 75% revision</li> <li>* 25% amputation</li> </ul>	2 years	<ul style="list-style-type: none"> <li>* 13% failed because of an infection.</li> <li>* 50% of infected prostheses had revision with the same prosthesis, 25% with a different prosthesis and 25% underwent amputation.</li> <li>* Patients receiving revision endoprostheses were not at increased risk for a subsequent revision or amputation compared to primary endoprostheses reconstruction.</li> </ul>
Zajonz 2016 [50]	Retrospective cohort 1994–2014 Excluded	N = 34 Modular endoprostheses of the lower extremity for infection	X	72 months (6-267 months)	<ul style="list-style-type: none"> <li>* Reinfection rate after healed reinfection in silver group was 40%, in the non-silver group 57% (1f).</li> </ul>
Zajonz 2017 [51]	Retrospective cohort 1994–2011	N = 101 45 tumor Modular endoprostheses of the lower extremity	<ul style="list-style-type: none"> <li>* 62% 2-SR</li> <li>* 11% resection</li> <li>* 11% arthrodesis</li> <li>* 8% DAIR</li> <li>* 8% amputation</li> </ul>	27 months (5-179 months)	<ul style="list-style-type: none"> <li>* 17.7% had infection (3 early infections, 16 late infections), reinfection rate 37%.</li> <li>* 36.6% CNS, 26.3% Staph epidermidis, 15.8% Staph aureus (1d).</li> <li>* Patients with infection had same age and sex, but higher BMI.</li> <li>* Prosthesis for tumors had fewer infections than other indications (8.9% vs. 21.7%).</li> </ul>

of strong levels of evidence published in the form of meta-analyses or randomized controlled trials, we compiled a narrative review discussing various factors associated with infection control in oncologic endoprostheses.

### Search Strategy

A literature search was performed in PubMed with relevant search terms on the 23<sup>rd</sup> of January 2018. The literature search resulted in 83 hits. Additional articles for screening were selected from the reference lists. Articles that were not written in English or did not have full text available were excluded. Twenty-nine articles were excluded based on title and abstract. Another 4 articles were excluded after thorough reading of the full text articles, whereby we included 41 articles in our literature analysis (see Tables 3 and 4).

DAIR procedure is one of the treatment approaches described for PJI of endoprostheses in cancer patients. However, treatment outcomes after DAIR are very variable and unpredictable in an oncology setting. Success rates vary between 39-70% [1,9-12]. Some of the reported factors that are associated with better outcomes after DAIR include superficial early infection, short duration of symptoms, well-fixed implants and well-characterized microbiology demonstrating a highly susceptible pathogen [13-15]. Unfortunately, the studies that reported on DAIR outcomes have very variable periods of clinical follow-up (34 months-10 years).

The most common microorganisms causing infection of oncological endoprostheses are *Staphylococcus aureus* and coagulase negative staphylococci, both account for > 50% of PJI. A large number of the documented infections were also polymicrobial infections accounting for 21-45% of cases [1,4,7,8,16]. There was no difference between monomicrobial and polymicrobial infections regarding outcome [4]. A study by Peel et al. was the only report demonstrating that the majority of infections of endoprosthesis were caused by multi-resistant microorganisms [9]. In one study, the success of outcome for DAIR as well as for two-stage revision for PJI of endoprosthesis did not show any correlation with the infecting organism [2]. It is important to note that the aforementioned results are based on a small number of patients, making generalizability of the findings somewhat limited.

### REFERENCES

- [1] Dhanoa A, Ajit Singh V, Elbahri H. Deep infections after endoprosthetic replacement operations in orthopedic oncology patients. *Surg Infect (Larchmt)*. 2015;16:323-332. doi:10.1089/sur.2014.049.
- [2] Flint M, Griffin A, Bell R, Wunder J, Ferguson P. Two-stage revision of infected uncemented lower extremity tumor endoprostheses. *J Arthroplasty*. 2007;22:859-865. doi:10.1016/j.arth.2006.11.003.
- [3] Grimer R, Belthur M, Chandrasekar C, Carter S, Tillman R. Two-stage revision for infected endoprostheses used in tumor surgery. *Clin Orthop Relat Res*. 2002;395:193-203.
- [4] Jeys L, Grimer R, Carter S, Tillman R. Periprosthetic infection in patients treated for an orthopaedic oncological condition. *J Bone Joint Surg Am*. 2005;87:842-849. doi:10.2106/JBJS.C.01222.
- [5] Lee S, Oh J, Lee K, Yoo K, Kim H. Infection after prosthetic reconstruction in limb salvage surgery. *Int Orthop*. 2002;26:179-184. doi:10.1007/s00264-001-0328-y.
- [6] Morii T, Morioka H, Ueda T, Araki N, Hashimoto N, Kawai A, et al. Deep infection in tumor endoprosthesis around the knee: a multi-institutional study by the Japanese Musculoskeletal Oncology Group. *BMC Musculoskelet Disord*. 2013;14:1. doi:10.1186/1471-2474-14-51.
- [7] Funovics P, Hipfl C, Hofstaetter J, Puchner S, Kotz R, Dominkus M. Management of septic complications following modular endoprosthetic reconstruction of the proximal femur. *Int Orthop*. 2011;35:1437-1444. doi:10.1007/s00264-010-1054-0.
- [8] Harges J, Gebert C, Schwappach A, Ahrens H, Streitburger A, Winkelmann W, et al. Characteristics and outcome of infections associated with tumor endoprostheses. *Arch Orthop Trauma Surg*. 2006;126:289-296. doi:10.1007/s00402-005-0009-1.
- [9] Peel T, May D, Buising K, Thursky K, Slavin M, Choong P. Infective complications following tumour endoprosthesis surgery for bone and soft tissue tumours. *Eur J Surg Oncol*. 2014;40:1087-1094. doi:10.1016/j.ejso.2014.02.241.
- [10] Chambers CW, Proctor CM, Kabler PW. Bactericidal effect of low concentrations of silver. *J Am Water Works Assoc*. 1962;54:208-216. doi:10.1002/j.1551-8833.1962.tb00834.x.
- [11] Harges J, von Eiff C, Streitbuenger A, Balke M, Budny T, Henrichs MP, et al. Reduction of periprosthetic infection with silver-coated megaprostheses in patients with bone sarcoma. *J Surg Oncol*. 2010;101:389-395. doi:10.1002/jso.21498.
- [12] Henderson ER, Groundland JS, Pala E, Dennis JA, Wooten R, Cheong D, et al. Failure mode classification for tumor endoprostheses: retrospective review of five institutions and a literature review. *J Bone Joint Surg Am*. 2011;93:418-429. doi:10.2106/JBJS.J.00834.
- [13] Donati F, Di Giacomo G, D'Adamio S, Ziranu A, Careri S, Rosa M, et al. Silver-coated hip megaprosthesis in oncological limb salvage surgery. *BioMed Res Int*. 2016;2016:9079041. doi:10.1155/2016/9079041.
- [14] Morii T, Yabe H, Morioka H, Beppu Y, Chuman H, Kawai A, et al. Postoperative deep infection in tumor endoprosthesis reconstruction around the knee. *J Orthop Sci*. 2010;15:331-339. doi:10.1007/s00776-010-1467-z.
- [15] Gitelis S, Yergler JD, Sawlani N, Schiff A, Shott S. Short and long term failure of the modular oncology knee prosthesis. *Orthopedics*. 2008;31:362.
- [16] Manoso M, Boland P, Healey J, Cordeiro P. Limb salvage of infected knee reconstructions for cancer with staged revision and free tissue transfer. *Ann Plast Surg*. 2006;56:532-535. doi:10.1097/01.sap.0000203990.08414.ad.
- [17] Bus M, Szafiranski A, Sellevold S, Goryn T, Jutte P, Bramer J, et al. LUMiC endoprosthetic reconstruction after periacetabular tumor resection: short-term results. *Clin Orthop Relat Res*. 2017;475:686-695. doi:10.1007/s11999-016-4805-4.
- [18] Chambers C, Proctor C, Kabler P. Bactericidal effect of low concentrations of silver. *J Am Water Works Assoc*. 1962;54:208-216.
- [19] Donati F, Di Giacomo G, D'Adamio S, Ziranu A, Careri S, Rosa M, et al. Silver-coated hip megaprosthesis in oncological limb salvage surgery. *BioMed Res Int*. 2016;2016:1-6. doi:10.1155/2016/9079041.
- [20] Felden A, Vaz G, Kreps S, Anract P, Hamadouche M, Biau D. A cemented acetabular component with a reinforcement cross provides excellent medium-term fixation in total hip arthroplasty after pelvic irradiation. *Bone Joint J*. 2015;97-B:177-184. doi:10.1302/0301-620X.97B2.34545.

TABLE 3. Exclusion after reading full text article

Author and Year	Reason for Exclusion
Massin, 1995 [36]	No tumorprosthesis, radiation followed by reconstruction with normal prosthesis, 2 late infections (2yr) of 71 cases, both girdlestone
Mittermayer, 2002 [40]	No information on infection, only on aseptic revision in retrospective cohort
Sherman, 2008 [45]	Case report
Zajonz, 2016 [50]	No tumorprostheses, only modular endoprostheses after PJI

TABLE 4. Exclusion after screening abstract and title

Author and Year	Reason for Exclusion
Aponte-Tinao, 2016 [52]	Does not answer the research question
Ascherl, 2010 [53]	Article in German language
Baker, 2011 [54]	Does not answer the research question
Bielack, 1999 [55]	Article in German language
Bosetti, 2002 [56]	Does not answer the research question
Brigman, 2003 [57]	Does not answer the research question
Buttaro, 2005 [58]	Does not answer the research question
Cho, 2005 [59]	Does not answer the research question
Deelstra, 2013 [60]	Does not answer the research question
Dieckmann, 2014 [61]	Does not answer the research question
Falkinstein, 2008 [62]	Does not answer the research question
Foo, 2011 [63]	Does not answer the research question
Gebert, 2010 [64]	Does not answer the research question
Glehr, 2013 [65]	Does not answer the research question
Gooding, 2011 [66]	Does not answer the research question
Gosheger, 2004 [67]	Does not answer the research question
Goulding, 2017 [68]	Does not answer the research question
Hillmann, 2000 [69]	Does not answer the research question
Ji, 2012 [70]	Article in Chinese language
Kühne, 2003 [71]	Does not answer the research question
Lautenschlager, 1976 [72]	Does not answer the research question
MacMull, 2010 [73]	Does not answer the research question
Mäkinen, 2017 [74]	Does not answer the research question
Malhotra, 2012 [75]	Does not answer the research question
Meek, 2004 [76]	Does not answer the research question
Nazar, 1999 [77]	Article in Polish language
Nebelung, 2000 [78]	Does not answer the research question
Niculescu, 2008 [79]	Does not answer the research question
Nobile, 2015 [80]	Article in Italian language
Pala, 2017 [81]	Does not answer the research question
Radunovic, 2016 [82]	Does not answer the research question
Schmolders, 2017 [83]	Article in German language
Sudmann, 1994 [84]	Does not answer the research question
Vcelak, 2017 [85]	Article in Czech language
Wang, 2011 [86]	Article in Chinese language
Wicart, 2002 [87]	Does not answer the research question
Wilding, 2016 [88]	Does not answer the research question
Wise, 1990 [89]	Does not answer the research question
Yoshida, 2010 [90]	Does not answer the research question

- [21] Gitelis S, Yergler J, Sawlani N, Schiff A, Shott S. Short and long term failure of the modular oncology knee prosthesis. *Orthopedics*. 2008;31:362.
- [22] Harges J, Ahrens H, Gebert C, Streibuerger A, Buerger H, Erren M, et al. Lack of toxicological side-effects in silver-coated megaprotheses in humans. *Biomaterials*. 2007;28:2869-2875. doi:10.1016/j.biomaterials.2007.02.033.
- [23] Harges J, von Eiff C, Streibuerger A, Balke M, Budny T, Henrichs M, et al. Reduction of periprosthetic infection with silver-coated megaprotheses in patients with bone sarcoma. *J Surg Oncol*. 2010;101:389-395. doi:10.1002/jso.21498.
- [24] Henderson E, Groundland J, Pala E, Dennis J, Wooten R, Cheong D, et al. Failure mode classification for tumor endoprotheses: retrospective review of five institutions and a literature review. *J Bone Joint Surg Am*. 2011;93:418-429. doi:10.2106/JBJS.J.00834.
- [25] Hollinger M. Toxicological aspects of topical silver pharmaceuticals. *Crit Rev Toxicol*. 1996;26:255-260.
- [26] Hsu R, Sim F, Chao E. Reoperation results after segmental prosthetic replacement of bone and joint for limb salvage. *J Arthroplasty*. 1999;14:519-256.
- [27] Jacobs J, Kull L, Frey G, Gitelis S, Sheinkop M, Kramer T, et al. Early failure of acetabular components inserted without cement after previous pelvic irradiation. *J Bone Joint Surg Am*. 1995;77:1829-1835. doi:10.2106/00004623-199512000-00006.
- [28] Jeys L, Grimer R, Carter S, Tillman R. Risk of amputation following limb salvage surgery with endoprosthetic replacement, in a consecutive series of 1261 patients. *Int Orthop*. 2003;27:160-163. doi:10.1007/s00264-003-0429-x.
- [29] Jeys L, Grimer R, Carter S, Tillman R, Abudu A. Post operative infection and increased survival in osteosarcoma patients: are they associated? *Ann Surg Oncol*. 2007;14:2887-2895. doi:10.1245/s10434-007-9483-8.
- [30] Jeys L, Luscombe J, Grimer R, Abudu A, Tillman R, Carter S. The risks and benefits of radiotherapy with massive endoprosthetic replacement. *J Bone Joint Surg Br*. 2007;89-B:1352-1355. doi:10.1302/0301-620X.89B10.19233.
- [31] Jeys L, Grimer R. The long-term risks of infection and amputation with limb salvage surgery using endoprotheses. *Recent Results Cancer Res*. 2009;179:75-84.
- [32] Kaminski P, Szmyd J, Ambrozy J, Jaworski J, Franczuk B. A comparison of outcomes of treatment with resection prosthesis of the hip in revision and oncological surgery. *Ortop Traumatol Rehabil*. 2017;19:145-156.
- [33] Kim K. Uncemented total hip arthroplasty in patients with a history of pelvic irradiation for prostate cancer. *J Bone Joint Surg Am*. 2007;89:798-805. doi:10.2106/JBJS.F.00183.
- [34] Lansdown A. A pharmacological and toxicological profile of silver as an antimicrobial agent in medical devices. *Adv Pharmacol Sci*. 2010;2010:1-16. doi:10.1155/2010/910686.
- [35] Li X, Moretti V, Ashana A, Lackman R. Perioperative infection rate in patients with osteosarcomas treated with resection and prosthetic reconstruction. *Clin Orthop Relat Res*. 2011;469:2889-2894. doi:10.1007/s11999-011-1877-z.
- [36] Massin P, Duparc J. Total hip replacement in irradiated hips: a retrospective study of 71 cases. *J Bone Joint Surg Br*. 1995;77:847-852.
- [37] Mavrogenis A, Pala E, Angelini A, Calabro T, Romagnoli C, Romantini M, et al. Infected prostheses after lower-extremity bone tumor resection: clinical outcomes of 100 patients. *Surg Infect*. 2015;16:267-275. doi:10.1089/sur.2014.085.
- [38] Mavrogenis AF, Papagelopoulos PJ, Coll-Mesa L, Pala E, Guerra G, Ruggieri P. Infected tumor prostheses. *Orthopedics*. 2011;34:991-998. doi:10.3928/01477447-20111021-24.
- [39] McDonald D, Capanna R, Gherlinzoni F, Bacci G, Ferruzzi A, Casadei R, et al. Influence of chemotherapy on perioperative complications in limb salvage surgery for bone tumors. *Cancer*. 1990;65:1509-1516. doi:10.1002/1097-0142(19900401)65:7<1509::AID-CNCR2820650710>3.0.CO;2-1.
- [40] Mittermayer F, Windhager R, Dominkus M, Krepler P, Schwameis E, Sluga M, et al. Revision of the Kotz type of tumor endoprosthesis for the lower limb. *J Bone Joint Surg Br*. 2002;84:401-406.
- [41] Morii T, Yabe H, Morioka H, Beppu Y, Chuman H, Kawai A, et al. Postoperative deep infection in tumor endoprosthesis reconstruction around the knee. *J Orthop Sci*. 2010;15:331-339. doi:10.1007/s00776-010-1467-z.
- [42] Pilge H, Gradl G, von Eisenhart-Rothe R, Gollwitzer H. Incidence and outcome after infection of megaprotheses. *Hip Int*. 2012;22:83-90.
- [43] Racano A, Pazionis T, Farrokhhyar F, Dehesi B, Ghert M. High infection rate outcomes in long-bone tumor surgery with endoprosthetic reconstruction in adults: a systematic review. *Clin Orthop Relat Res*. 2013;471:2017-2027. doi:10.1007/s11999-013-2842-9.
- [44] Renard A, Veth R, Schreuder H, van Loon C, Kooops H, van Horn J. Function and complications after ablative and limb-salvage therapy in lower extremity sarcoma of bone. *J Surg Oncol*. 2000;73:198-205. doi:10.1002/(SICI)1096-9098(200004)73:4<198::AID-JSO3>3.0.CO;2-X.
- [45] Sherman S, Cunneen K, Walcott-Sapp S, Brause B, Westrich G. Custom total femur spacer and second-stage total femur arthroplasty as a novel approach to infection and periprosthetic fracture. *J Arthroplasty*. 2008;23:781-786. doi:10.1016/j.arth.2007.05.027.
- [46] Shin D, Weber K, Chao E, An K, Sim F. Reoperation for failed prosthetic replacement used for limb salvage. *Clin Orthop Relat Res*. 1999;358:53-63.
- [47] Sim I, Tse L, Ek E, Powell G, Choong P. Salvaging the limb salvage: management of complications following endoprosthetic reconstruction for tumours around the knee. *Eur J Surg Oncol*. 2007;33:796-802. doi:10.1016/j.ejso.2006.10.007.
- [48] Wafa H, Grimer R, Reddy K, Jeys L, Abudu A, Carter S, et al. Retrospective evaluation of the incidence of early periprosthetic infection with silver-

- treated endoprostheses in high-risk patients: case-control study. *Bone Joint J.* 2015;97-B:252-257. doi:10.1302/0301-620X.97B2.34554.
- [49] Wirganowicz P, Eckardt J, Dorey F, Eilber F, Kabo J. Etiology and results of tumor endoprosthesis revision surgery in 64 patients. *Clin Orthop Relat Res.* 1999;358:64-74.
- [50] Zajonc D, Zieme A, Prietzel T, Moche M, Tjepoldt S, Roth A, et al. Periprosthetic joint infections in modular endoprostheses of the lower extremities: a retrospective observational study in 101 patients. *Patient Saf Surg.* 2016;10:1-9. doi:10.1186/s13037-016-0095-8.
- [51] Zajonc D, Birke U, Ghanem M, Prietzel T, Josten C, Roth A, et al. Silver-coated modular megaendoprostheses in salvage revision arthroplasty after periprosthetic infection with extensive bone loss - a pilot study of 34 patients. *BMC Musculoskelet Disord.* 2017;18:1-7. doi:10.1186/s12891-017-1742-7.
- [52] Aponte-Tinco L, Ayerza M, Muscolo D, Farfalli G. What are the risk factors and management options for infection after reconstruction with massive bone allografts? *Clin Orthop Relat Res.* 2016;474:669-673. doi:10.1007/s11999-015-4353-3.
- [53] Ascherl R. Infection management of megaimplants. *Orthopade.* 2010;39:980-993.
- [54] Baker R, Duncan C. Acyclic acetabular roof reconstruction for severe superior segmental acetabular bone loss in 2-stage surgery for infected hip arthroplasty. *J Arthroplasty.* 2011;26:1567-1569. doi:10.1016/j.arth.2011.05.002.
- [55] Bielack S, Kempf-Bielack B, Schwenger D, Birkfellner T, Dellling G, Ewerbeck V, et al. Neoadjuvant therapy for localized osteosarcoma of extremities. Results for the cooperative osteosarcoma study group COSS of 925 patients. *Klin Padiatr.* 1999;211:260-270.
- [56] Bosetti M, Masse A, Tobin E, Cannas M. Silver coated materials for external fixation devices: in vitro biocompatibility and genotoxicity. *Biomaterials.* 2002;23:887-892. doi:10.1016/S0142-9612(01)00198-3.
- [57] Brigman B, Kumagai S, McGuire M. Rotationplasty after failed limb-sparing tumor surgery. *Clin Orthop Relat Res.* 2003;415:254-260. doi:10.1097/01.blo.0000093887.12372.3d.
- [58] Buttaro M. Vancomycin-supplemented impacted bone allografts in infected hip arthroplasty: two-stage revision results. *J Bone Joint Surg Br.* 2005;87-B:314-319. doi:10.1302/0301-620X.87B3.14788.
- [59] Cho M, Kwun K, Lee D, Kim S, Kim J. Latent period best predicts acetabular cup failure after total hip arthroplasties in radiated hips. *Clin Orthop Relat Res.* 2005;438:165-170. doi:10.1097/01.blo.0000167671.10820.29.
- [60] Deelstra J, Neut D, Jutte P. Successful treatment of candida albicans-infected total hip prosthesis with staged procedure using an antifungal-loaded cement spacer. *J Arthroplasty.* 2013;28:374.e5-374.e8. doi:10.1016/j.arth.2012.04.034.
- [61] Dieckmann R, Schulz D, Gosheger G, Becker K, Daniilidis K, Streitbürger A, et al. Two-stage hip revision arthroplasty with a hexagonal modular cementless stem in cases of periprosthetic infection. *BMC Musculoskelet Disord.* 2014;15:398. doi:10.1186/1471-2474-15-398.
- [62] Falkenstein Y, Ahlmann E, Menendez L. Reconstruction of type II pelvic resection with a new peri-acetabular reconstruction endoprosthesis. *J Bone Joint Surg Br.* 2008;90:371-376. doi:10.1302/0301-620X.90B3.20144.
- [63] Foo L, Harges J, Henrichs M, Ahrens H, Gosheger G, Streitbürger A. Surgical difficulties encountered with use of modular endoprosthesis for limb preserving salvage of failed allograft reconstruction after malignant tumor resection. *J Arthroplasty.* 2011;26:744-750. doi:10.1016/j.arth.2010.06.011.
- [64] Gebert C, Wessling M, Götze C, Gosheger G, Harges J. The modular universal tumour and revision system (MUTARS®) in endoprosthesis revision surgery. *Int Orthop.* 2010;34:1261-1265. doi:10.1007/s00264-010-1007-7.
- [65] Glehr M, Leithner A, Friesenbichler J, Goessler W, Avian A, Andreou D, et al. Argyria following the use of silver-coated megaprotheses: no association between the development of local argyria and elevated silver levels. *Bone Joint J.* 2013;95 B:988-992. doi:10.1302/0301-620X.95B7.31124.
- [66] Gooding C, Masri B, Duncan C, Greidanus N, Garbuz D. Durable infection control and function with the PROSTALAC spacer in two-stage revision for infected knee arthroplasty. *Clin Orthop Relat Res.* 2011;469:985-993. doi:10.1007/s11999-010-1579-y.
- [67] Gosheger G, Harges J, Ahrens H, Streitbürger A, Buerger H, Erren M, et al. Silver-coated megaendoprostheses in a rabbit model - an analysis of the infection rate and toxicological side effects. *Biomaterials.* 2004;25:5547-5556. doi:10.1016/j.biomaterials.2004.01.008.
- [68] Goulding K, Schwartz A, Hattrup S, Randall R, Lee D, Rispoli D, et al. Use of compressive osseointegration endoprostheses for massive bone loss from tumor and failed arthroplasty: a viable option in the upper extremity. *Clin Orthop Relat Res.* 2017;475:1752. doi:10.1007/s11999-017-5299-4.
- [69] Hillmann A, Gosheger G, Hoffmann C, Ozaki T, Winkelmann W. Rotationplasty-surgical treatment modality after failed limb salvage procedure. *Arch Orthop Trauma Surg.* 2000;120:555-558.
- [70] Ji T, Guo W, Yang R, Tang X. Two-stage revision for prosthesis infection in patients with bone tumor after knee prosthetic replacement. *Zhongguo Xiu Fu Chong Jian Wai Ke Za Zhi.* 2012;26:21-25.
- [71] Kühne C, Taeger G, Nast-Kolb D, Ruchholtz S. Knee arthrodesis after infected tumor mega prosthesis of the knee using an intramedullary nail for callus distraction. *Langenbecks Arch Surg Dtsch Ges Für Chir.* 2003;388:56-59. doi:10.1007/s00423-003-0360-z.
- [72] Lautenschlager E, Jacobs J, Marshall G, Meyer P. Mechanical properties of bone cements containing large doses of antibiotic powders. *J Biomed Mater Res.* 1976;10:929-938. doi:10.1002/jbm.820100610.
- [73] Macmull S, Bartlett W, Miles J, Blunn G, Pollock R, Carrington R, et al. Custom-made hinged spacers in revision knee surgery for patients with infection, bone loss and instability. *Knee.* 2010;17:403-406. doi:10.1016/j.knee.2009.11.004.
- [74] Mäkinen T, Abolghasemian M, Watts E, Fichman S, Kuzyk P, Safir O, et al. Management of massive acetabular bone defects in revision arthroplasty of the hip using a reconstruction cage and porous metal augment. *Bone Joint J.* 2017;99B:607-613. doi:10.1302/0301-620X.99B5.BJ-2016-0264.R3.
- [75] Malhotra R, Kancherla R, Kumar V, Soral A. Trabecular metal acetabular revision system (cup-cage construct) to address the massive acetabular defects in revision arthroplasty. *Indian J Orthop.* 2012;46:483. doi:10.4103/0019-5413.97264.
- [76] Meek R, Dunlop D, Garbuz D, McGraw R, Greidanus N, Masri B. Patient satisfaction and functional status after aseptic versus septic revision total knee arthroplasty using the PROSTALAC articulating spacer. *J Arthroplasty.* 2004;19:874-879. doi:10.1016/j.arth.2004.06.028.
- [77] Nazar J, Marciniak W, Szulc A, Rogala P, Posadzky P, Piontek T, et al. Complications after joint endoprosthesis for treatment of locomotor system neoplasms. *Chir Narzadow Ruchu Ortop Pol.* 1999;64:489-495.
- [78] Nebelung W, Birger T, Röpke M, Neumann H. Rotationplasty as a salvage procedure in revision of tumor endoprosthesis of the distal femur - a report of two cases. *Arch Orthop Trauma Surg.* 2000;120:541-543. doi:10.1007/s004029900107.
- [79] Niculescu M, Negrusoiu M. Deep recurrent infection of the hip after tumoral resection in an 18-years old male - a case report. *J Med Life.* 2008;1:439-442.
- [80] Nobile M, Navone P, Domeniconi G, Della Valle A, Daolio P, Buccino N, et al. Surgical site infections in oncologic orthopaedic prosthetic surgery. *Ann Ig.* 2015;27:711-717.
- [81] Pala E, Trovarelli G, Angelini A, Maraldi M, Berizzi A, Ruggieri P. Megaprosthesis of the knee in tumor and revision surgery. *Acta Biomed.* 2017;88:129-138.
- [82] Radunović A, Košutić M, Vulović M, Milev B, Janjušević N, Ivošević A, et al. Ilizarov method as limb salvage in treatment of massive femoral defect after unsuccessful tumor arthroplasty. *Vojnosanit Pregl.* 2016;73:779-782. doi:http://dx.doi.org/10.2298/VSP150419039R.
- [83] Schmolders J, Koob S, Schepers P, Gravius S, Wirtz D, Burger C, et al. The role of a modular universal tumour and revision system (MUTARS) in lower limb endoprosthesis revision surgery - outcome analysis of 25 patients. *Z Orthop Unf.* 2017;155:61-66.
- [84] Sudmann E, Vik H, Rait M, Todnem K, Andersen K, Julsham K, et al. Systemic and local silver accumulation after total hip replacement using silver-impregnated bone cement. *Med Prog Technol.* 1994;20:179-184.
- [85] Vcelak J, Matejovsky Jr Z, Kofranek I, Kubes R, Lesensky J. Periprosthetic infection of the knee megaprosthesis following a resection of malignant tumours around the knee. *Acta Chir Orthop Traumatol Cech.* 2017;84:46-51.
- [86] Wang J, Shen J, Yin J, Huang G, Lu J, Li H, et al. Effectiveness evaluation of prosthetic revision for aseptic loosening in oncology prosthesis. *Zhongguo Xiu Fu Chong Jian Wai Ke Za Zhi.* 2011;25:1414-1417.
- [87] Wicart P, Mascard E, Missenard G, Dubousset J. Rotationplasty after failure of a knee prosthesis for a malignant tumour of the distal femur. *J Bone Joint Surg Br.* 2002;84:865-869. doi:10.1302/0301-620X.84B6.13043.
- [88] Wilding C, Cooper G, Freeman A, Parry M, Jeys L. Can a silver-coated arthrodesis implant provide a viable alternative to above knee amputation in the unsalvageable, infected total knee arthroplasty? *J Arthroplasty.* 2016;31:2542-2547. doi:10.1016/j.arth.2016.04.009.
- [89] Wise MW 3rd, Robertson I, Lachiewicz P, Thrall D, Metcalf M. The effect of radiation therapy on the fixation strength of an experimental porous-coated implant in dogs. *Clin Orthop Relat Res.* 1990;261:276-280.
- [90] Yoshida S, Yokoyama R, Sakamoto A. Treatment of pelvic defect and infection with endoprosthesis exposure by topical negative pressure and irrigation with myocutaneous flap. *Microsurgery.* 2010;31:655-658. doi:10.1002/micr.

## 2.2. TREATMENT: ONE-STAGE EXCHANGE

**Authors:** Michiel van de Sande, Hiroyuki Tsuchiya, Daisuke Inoue

### QUESTION 1: Does the use of iodine-coated or silver-coated implants make one-stage exchange arthroplasty possible in the management of patients with infected oncologic endoprosthesis?

**RECOMMENDATION:** Unknown. Current literature has advocated the advantages of surface-modified coating (e.g., silver-coated, iodine-supported implants). Recently, there have been several low-quality, small-scale studies showing promising results for using surface-modified implants in one-stage exchange arthroplasty to treat infected oncologic endoprosthesis. However, to date there remains unsubstantiated evidence and large-scale, high-level evidence studies are necessitated.

**LEVEL OF EVIDENCE:** Limited

**DELEGATE VOTE:** Agree: 100%, Disagree: 0%, Abstain: 0% (Unanimous, Strongest Consensus)

#### RATIONALE

The basic treatment for malignant musculoskeletal tumors is a combination of surgical treatment with adjuvant radiation and chemotherapy. Specifically, limb salvage surgery is becoming the standard treatment for oncologic patients, because the effectiveness of chemotherapy has immensely improved in recent decades [1]. Prosthetic reconstruction using an endoprosthesis provides the best possible level of functionality in patients who require a wide excision for a malignant bone or soft tissue tumor because of improved surgical techniques and implant devices. However, periprosthetic joint infection (PJI) continues to be a serious complication after the placement of an endoprosthesis and is not uncommon to observe [2]. Prior literature has demonstrated that the infection rate of an endoprosthesis ranged from 4-36% [3-6]. Therefore, prevention of PJI becomes an essential task for success, particularly in this patient population. An increasingly popular method used in preventing PJI is the utilization of surface-modified implants with antimicrobial effects, such as iodine-coated or silver-coated implants.

Silver has been widely investigated because of its strong broad-spectrum antibacterial properties, anti-biofilm potential and low cytotoxicity [7-11]. Currently, there are several case series and a few case control studies that examine the success of one-stage revision arthroplasty using silver-coated implants for infected oncologic endoprostheses [12-17]. In a case series of four infected endoprostheses, Zajonz et al. demonstrated that one-stage revision arthroplasty resulted in no subsequent reinfection of the endoprostheses [17]. Wafa et al. [16] conducted a case-control study comparing outcomes for silver-coated prosthesis versus unmodified prosthesis in oncologic patients. In terms of single-stage revisions, they noted a lower rate of infection in the silver group compared to the control group, although this was not statistically significant (5.1% vs. 12.5%;  $p = 0.249$ ). There was, however, a marginally significant decrease in infection rate for two-stage revisions with silver-coated implants (15% vs. 42.9%;  $p = 0.05$ ). Harges et al. reported that patients who initially underwent placement of a silver-coated prosthesis ( $n = 51$ ) had reduced total infection rates [13]. In addition, the infections that did develop required less aggressive treatment compared to the titanium implant control group ( $n = 74$ ). Similar findings were later produced by the same team for endoprostheses involving the proximal tibia in patients with sarcoma [18].

Iodine-supported implants also exemplify strong inhibition of biofilm formation by preventing antibacterial attachment on metal surfaces similar to silver-coated implants [19-21]. There are three clinical reports that suggest the effectiveness of iodine-supported implants for patients with malignant bone or soft-tissue tumor

[19-22]. Shira et al. showed that both one-stage ( $n = 11$ ) and two-stage ( $n = 15$ ) exchange arthroplasty with iodine-supported implants were sufficient to treat infection without need for additional surgery in all cases [19]. However, it is noted that one-stage revision surgery was employed for inactive or quiescent infections and two-stage revision surgery was indicated for active infections (defined by "active sinus discharge or abscess formation or C-reactive protein (CRP)  $> 0.5$  mg/dl"). Nevertheless, there is a need for prospective case-control studies or randomized controlled trials investigating the use of iodine-supported implants in one-stage revision arthroplasty.

In conclusion, it is uncertain whether silver- or iodine-modified implants are effective for one-stage revision arthroplasty in infected oncologic endoprosthesis based on limited literature. There are a few studies in circulation that are promising and advocate for their success in one-stage revision surgery for eradicating infection. This investigative team believes that additional larger-scale investigations involving randomized control trials, prospective cohort and case-control studies are warranted.

#### REFERENCES

- [1] Kadam D. Limb salvage surgery. *Indian J Plast Surg.* 2013;46:265-274. doi:10.4103/0970-0358.118603.
- [2] Harges J, Gebert C, Schwappach A, Ahrens H, Streitburger A, Winkelmann W, et al. Characteristics and outcome of infections associated with tumor endoprostheses. *Arch Orthop Trauma Surg.* 2006;126:289-296. doi:10.1007/s00402-005-0009-1.
- [3] Zajonz D, Wuthe L, Tiepolt S, Brandmeier P, Prietzel T, von Salis-Soglio GF, et al. Diagnostic work-up strategy for periprosthetic joint infections after total hip and knee arthroplasty: a 12-year experience on 320 consecutive cases. *Patient Saf Surg.* 2015;9:20. doi:10.1186/s13037-015-0071-8.
- [4] Pala E, Trovarelli G, Calabrò T, Angelini A, Abati CN, Ruggieri P. Survival of modern knee tumor megaprostheses: failures, functional results, and a comparative statistical analysis. *Clin Orthop Relat Res.* 2015;473:891-899. doi:10.1007/s11999-014-3699-2.
- [5] Sevelde F, Schuh R, Hofstaetter JG, Schinhan M, Windhager R, Funovics PT. Total femur replacement after tumor resection: limb salvage usually achieved but complications and failures are common. *Clin Orthop Relat Res.* 2015;473:2079-2087. doi:10.1007/s11999-015-4282-1.
- [6] Capanna R, Scoccianti G, Frenos F, Vilardi A, Beltrami G, Campanacci DA. What was the survival of megaprostheses in lower limb reconstructions after tumor resections? *Clin Orthop Relat Res.* 2015;473:820-830. doi:10.1007/s11999-014-3736-1.
- [7] Nganga S, Travan A, Marsich E, Donati I, Söderling E, Moritz N, et al. In vitro antimicrobial properties of silver-polysaccharide coatings on porous fiber-reinforced composites for bone implants. *J Mater Sci Mater Med.* 2013;24:2775-2785. doi:10.1007/s10856-013-5022-2.
- [8] Marsich E, Travan A, Donati I, Turco G, Kulkova J, Moritz N, et al. Biological responses of silver-coated thermosets: an in vitro and in vivo study. *Acta Biomater.* 2013;9:5088-5099. doi:10.1016/j.actbio.2012.10.002.
- [9] Politano AD, Campbell KT, Rosenberger LH, Sawyer RG. Use of silver in the prevention and treatment of infections: silver review. *Surg Infect (Larchmt).* 2013;14:8-20. doi:10.1089/sur.2011.097.

- [10] Gallo J, Panacek A, Prucek R, Kriegova E, Hradilova S, Hobza M, et al. Silver nanocoating technology in the prevention of prosthetic joint infection. *Materials (Basel)*. 2016;9. doi:10.3390/ma9050337.
- [11] Brennan SA, Ní Fhoghlú C, Devitt BM, O'Mahony FJ, Brabazon D, Walsh A. Silver nanoparticles and their orthopaedic applications. *Bone Joint J*. 2015;97-B:582-589. doi:10.1302/0301-620X.97B5.33336.
- [12] Harges J, Ahrens H, Gebert C, Streitbueger A, Buerger H, Erren M, et al. Lack of toxicological side-effects in silver-coated megaprotheses in humans. *Biomaterials*. 2007;28:2869-2875. doi:10.1016/j.biomaterials.2007.02.033.
- [13] Harges J, von Eiff C, Streitbueger A, Balke M, Budny T, Henrichs MP, et al. Reduction of periprosthetic infection with silver-coated megaprotheses in patients with bone sarcoma. *J Surg Oncol*. 2010;101:389-395. doi:10.1002/jso.21498.
- [14] Harges J, Henrichs M-P, Gosheger G, Guder W, Nottrott M, Andreou D, et al. Tumour endoprosthesis replacement in the proximal tibia after intrarticular knee resection in patients with sarcoma and recurrent giant cell tumour. *Int Orthop*. 2018;March 22. doi:10.1007/s00264-018-3893-z.
- [15] Glehr M, Leithner A, Friesenbichler J, Goessler W, Avian A, Andreou D, et al. Argyria following the use of silver-coated megaprotheses: no association between the development of local argyria and elevated silver levels. *Bone Joint J*. 2013;95-B:988-992. doi:10.1302/0301-620X.95B7.31124.
- [16] Wafa H, Grimer RJ, Reddy K, Jeys L, Abudu A, Carter SR, et al. Retrospective evaluation of the incidence of early periprosthetic infection with silver-treated endoprotheses in high-risk patients: case-control study. *Bone Joint J*. 2015;97-B:252-257. doi:10.1302/0301-620X.97B2.34554.
- [17] Zajonz D, Birke U, Ghanem M, Prietzel T, Josten C, Roth A, et al. Silver-coated modular megaendoprotheses in salvage revision arthroplasty after peri-implant infection with extensive bone loss - a pilot study of 34 patients. *BMC Musculoskelet Disord*. 2017;18:383. doi:10.1186/s12891-017-1742-7.
- [18] Harges J, Henrichs MP, Hauschild G, Nottrott M, Guder W, Streitbueger A. Silver-coated megaprosthesis of the proximal tibia in patients with sarcoma. *J Arthroplasty*. 2017;32:2208-2213. doi:10.1016/j.arth.2017.02.054.
- [19] Shirai T, Tsuchiya H, Nishida H, Yamamoto N, Watanabe K, Nakase J, et al. Antimicrobial megaprotheses supported with iodine. *J Biomater Appl*. 2014;29:617-623. doi:10.1177/0885328214539365.
- [20] Inoue D, Kabata T, Ohtani K, Kajino Y, Shirai T, Tsuchiya H. Inhibition of biofilm formation on iodine-supported titanium implants. *Int Orthop*. 2017;41:1093-1099. doi:10.1007/s00264-017-3477-3.
- [21] Tsuchiya H, Shirai T, Nishida H, Murakami H, Kabata T, Yamamoto N, et al. Innovative antimicrobial coating of titanium implants with iodine. *J Orthop Sci*. 2012;17:595-604. doi:10.1007/s00776-012-0247-3.
- [22] Shirai T, Tsuchiya H, Terauchi R, Tsuchida S, Mizoshiri N, Igarashi K, et al. The outcomes of reconstruction using frozen autograft combined with iodine-coated implants for malignant bone tumors: compared with non-coated implants. *Jpn J Clin Oncol*. 2016;46:735-740. doi:10.1093/jjco/hyw065.

**Authors:** Michelle Ghert, Roberto Velez, Johnathan R. Lex, Andrea Sallent, Philip Linke

## QUESTION 2: Is there a role for single-stage exchange arthroplasty for patients with infected oncologic endoprosthesis?

**RECOMMENDATION:** In principle, despite the lack of sufficient evidence, single-stage exchange arthroplasty can be performed in patients with infected oncologic endoprosthesis if the general requirements to perform a single-stage procedure are fulfilled. However, a single-stage revision without removing the anchorage components is not recommended, since better infection control can be achieved when prostheses were removed rather than salvaged.

**LEVEL OF EVIDENCE:** Limited

**DELEGATE VOTE:** Agree: 100%, Disagree: 0%, Abstain: 0% (Unanimous, Strongest Consensus)

### RATIONALE

Periprosthetic joint infections (PJIs) are serious complications of reconstruction of defects created by tumor resection. The reconstruction in tumor surgery usually involves the use of modular endoprotheses. Infection following tumor surgery and reconstruction is relatively common, occurring in 8 to 35% of primary implants [1-3]. As limb salvage surgery has gained popularity over the recent years, the number of reconstruction procedures after tumor resection, and the ensuing infections, have increased [1-3].

Despite the high incidence of PJI following oncologic reconstruction, and perhaps because of the relatively low volume of tumor reconstruction cases, there is a universal lack of high-quality studies related to PJI following oncologic reconstructions. The review of current available literature reveals only 12 relevant articles on infections following oncologic reconstructions using tumor endoprotheses. Only six published articles reported the outcomes of single-stage exchange arthroplasty [2,4-8]. However, it must be noted that some of the authors perform a single-stage revision with removal of all exchangeable and polyethylene components with debridement of surrounding soft tissues but without removal of the fixation anchoring components [2,4-8].

As presented by Buchholz et al. in the 1970s, the concept of classic single-stage exchange arthroplasty after infected total joint replacement is the radical debridement and removal of all foreign materials [9]. Morii et al. found that infection control rates were significantly higher when prostheses were removed rather than salvaged in a

series of 57 patients with PJI of tumor endoprotheses [4]. According to Harges et al., an optimal soft tissue condition is imperative for a successful limb salvage procedure [7].

Currently, there is no concrete evidence in the literature to answer the question, "What role, if any, does one-stage exchange arthroplasty play in the management of PJI after oncologic reconstruction using modular endoprotheses?" However, borrowing from the hip and knee adult reconstruction literature, one can state that the rate of infection control is usually better when all prosthetic and foreign material are removed and new implants used either at the same time (one-stage exchange) or at a later date. It is also an agreed principle that the rate of infection control correlates with the extent of debridement and bioburden reduction. Applying these principles, we can state that one-stage exchange arthroplasty does have a role in the management of acute or chronic PJI following oncologic reconstruction. The question that remains and is somewhat unique to oncologic reconstruction is whether all foreign material needs to be removed during one-stage exchange or some parts, such as the anchoring portion of the prosthesis in the bone, can be retained. The tendency would be to advocate that all foreign material should be removed during one-stage exchange. However, removal of the anchoring part of the prosthesis may not be possible or removal of this part may preclude a later reconstruction. Under these circumstances, sub-radical resection arthroplasty may be performed. It is critical, however, that the retained prosthesis is cleaned physi-

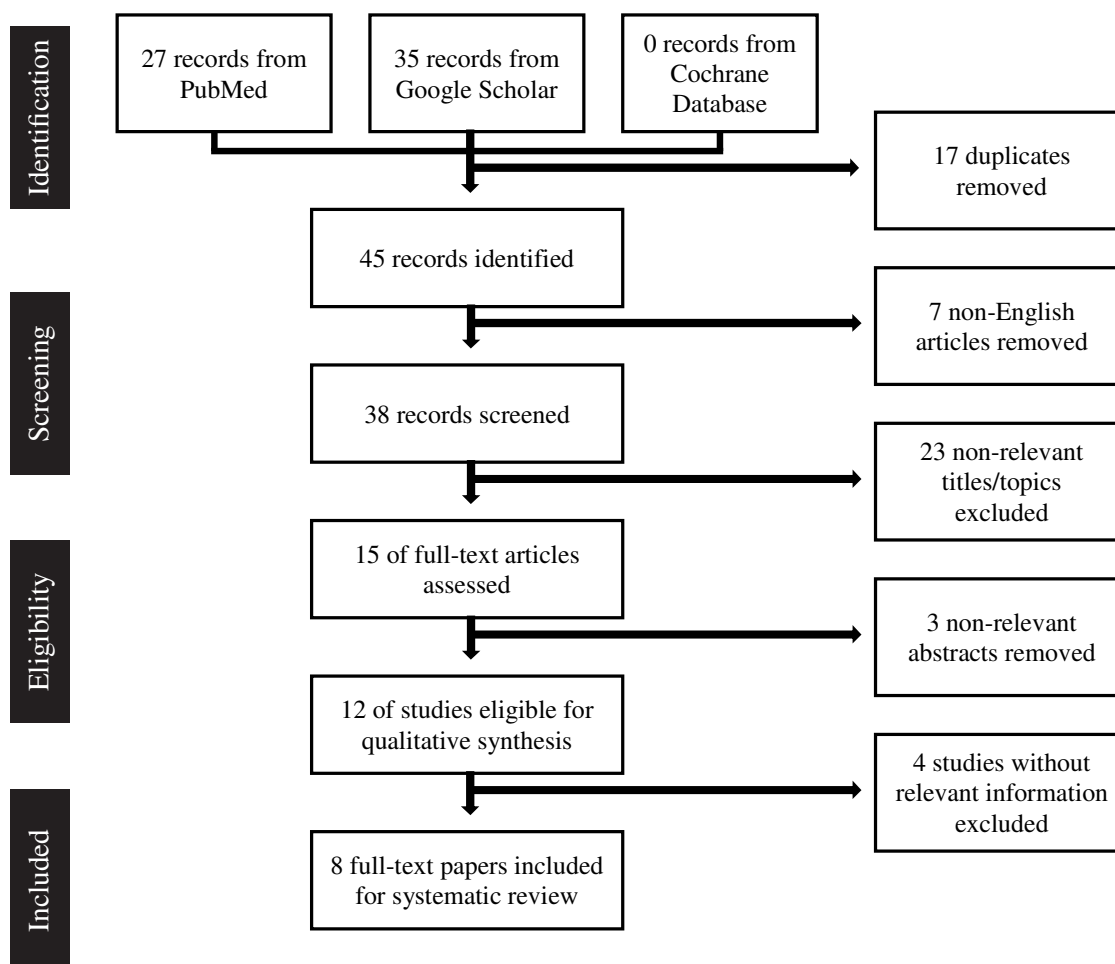


FIGURE 1. PRISMA Flowchart showing the identification of relevant studies during the review process.

cally and chemically with agents such as chlorhexidine or povidone iodine scrubs and washed thoroughly. Obeying the general principle of infection surgery is likely to allow some patients with infected oncologic prostheses to be treated by one-stage exchange arthroplasty. Future research is needed to determine which group of patients would most benefit from one-stage exchange arthroplasty versus two-stage exchange arthroplasty.

## REFERENCES

- [1] Rossi B, Zoccali C, Toma L, Ferraresi V, Biagini R. Surgical site infections in treatment of musculoskeletal tumors: experience from a single oncologic orthopedic institution. ResearchGate 2016. [https://www.researchgate.net/publication/304744960\\_Surgical\\_Site\\_Infections\\_in\\_Treatment\\_of\\_Musculoskeletal\\_Tumors\\_Experience\\_from\\_a\\_Single\\_Oncologic\\_Orthopedic\\_Institution](https://www.researchgate.net/publication/304744960_Surgical_Site_Infections_in_Treatment_of_Musculoskeletal_Tumors_Experience_from_a_Single_Oncologic_Orthopedic_Institution) (accessed July 18, 2018).
- [2] Funovics PT, Hipfl C, Hofstaetter JG, Puchner S, Kotz RI, Dominkus M. Management of septic complications following modular endoprosthetic reconstruction of the proximal femur. *Int Orthop*. 2011;35:1437-1444. doi:10.1007/s00264-010-1054-0.
- [3] Morii T, Yabe H, Morioka H, Beppu Y, Chuman H, Kawai A, et al. Postoperative deep infection in tumor endoprosthesis reconstruction around the knee. *J Orthop Sci*. 2010;15:331-339. doi:10.1007/s00776-010-1467-z.
- [4] Morii T, Morioka H, Ueda T, Araki N, Hashimoto N, Kawai A, et al. Deep infection in tumor endoprosthesis around the knee: a multi-institutional study by the Japanese Musculoskeletal Oncology Group. *BMC Musculoskelet Disord*. 2013;14:51. doi:10.1186/1471-2474-14-51.
- [5] Jeys LM, Grimer RJ, Carter SR, Tillman RM. Periprosthetic infection in patients treated for an orthopaedic oncological condition. *J Bone Joint Surg Am*. 2005;87:842-849. doi:10.2106/JBJS.C.01222.
- [6] Holzer G, Windhager R, Kotz R. One-stage revision surgery for infected megaprotheses. *J Bone Joint Surg Br*. 1997;79:31-35.
- [7] Harges J, Gebert C, Schwappach A, Ahrens H, Streiburger A, Winkelmann W, et al. Characteristics and outcome of infections associated with tumor endoprotheses. *Arch Orthop Trauma Surg*. 2006;126:289-296. doi:10.1007/s00402-005-0009-1.
- [8] Peel T, May D, Buising K, Thursky K, Slavin M, Choong P. Infective complications following tumour endoprosthesis surgery for bone and soft tissue tumours. *Eur J Surg Oncol*. 2014;40:1087-1094. doi:10.1016/j.ejso.2014.02.241.
- [9] Buchholz HW, Elson RA, Engelbrecht E, Lodenkämper H, Röttger J, Siegel A. Management of deep infection of total hip replacement. *J Bone Joint Surg Br*. 1981;63-B:342-353.



## 2.3. TREATMENT: RESEARCH CAVEATS

**Authors:** Germán Luis Farfalli, Peter Choong, Sam Francis

**QUESTION 1:** Should the management of periprosthetic joint infection (PJI) involving an oncologic endoprosthesis differ from that of conventional joint replacement prostheses?

**RECOMMENDATION:** No. The management of PJI involving an oncologic endoprosthesis is similar to that of conventional joint replacement prosthesis.

**LEVEL OF EVIDENCE:** Limited

**DELEGATE VOTE:** Agree: 100%, Disagree: 0%, Abstain: 0% (Unanimous, Strongest Consensus)

### RATIONALE

Deep infection of primary total joint arthroplasty (TJA) is a catastrophic complication. However, the infection rate is relatively low [1]. Tumor endoprosthesis are essentially larger implants similar to those used in total joint replacements, although the type of surgery and the risk factors related to the type of patient differ significantly [2,3]. Therefore, a deep infection with these types of implants drastically worsens the prognosis of the affected limb and significantly increases the risk of amputation compared to conventional prosthetic arthroplasties [2,3].

Despite these differences in the rate of complications between primary arthroplasties and endoprostheses, the management of postoperative infections is similar. There is a general consensus that infections are divided into either early or late infections, according to the time of diagnosis [4–9].

Despite the large amount of literature analyzing PJIs, there are no comparative studies between management and outcomes nor between primary prostheses and endoprosthesis. There are only a limited number of retrospective studies focused on the outcomes of periprosthetic infections in endoprostheses [10–13]. Therefore, the management of infections in endoprostheses is based on protocols used in primary prostheses. A new strategy that seems to be improving the results at the time of endoprostheses re-implant is silver-coated endoprostheses. Wafa et al. [14] suggests in a retrospective case-control study that the overall success rates in controlling infection by two-stage revision in patients treated with silver-coated endoprosthesis was 85%, compared to uncoated tumor prostheses ( $p = 0.05$ , Chi-square test). The Agluna-treated endoprostheses were associated with a lower rate of early periprosthetic infection. In addition, these silver-treated implants were particularly useful in two-stage revisions for infection and in those patients with incidental positive cultures at the time of implantation of the prosthesis. Finally, they conclude that debridement with antibiotic treatment and retention of the implant appeared to be more successful with silver-coated implants.

There is no consensus in the management of an infected endoprosthesis given the limited data. The current recommendation is based on treatment of infected primary arthroplasties.

### REFERENCES

- [1] Gehrke T, Alijanipour P, Parvizi J. The management of an infected total knee arthroplasty. *Bone Joint J.* 2015;97-B:20–29. doi:10.1302/0301-620X.97B10.36475.
- [2] Grimer RJ, Aydin BK, Wafa H, Carter SR, Jeys L, Abudu A, et al. Very long-term outcomes after endoprosthetic replacement for malignant tumours of bone. *Bone Joint J.* 2016;98-B:857–864. doi:10.1302/0301-620X.98B6.37417.
- [3] Henderson ER, Groundland JS, Pala E, Dennis JA, Wooten R, Cheong D, et al. Failure mode classification for tumor endoprostheses: retrospective review of five institutions and a literature review. *J Bone Joint Surg Am.* 2011;93:418–429. doi:10.2106/JBJS.00834.
- [4] Parvizi J, Adeli B, Zmistowski B, Restrepo C, Greenwald AS. Management of periprosthetic joint infection: the current knowledge: AAOS exhibit selection. *J Bone Joint Surg Am.* 2012;94:e104. doi:10.2106/JBJS.K.01417.
- [5] Osmon DR, Berbari EF, Berendt AR, Lew D, Zimmerli W, Steckelberg JM, et al. Executive summary: diagnosis and management of prosthetic joint infection: clinical practice guidelines by the Infectious Diseases Society of America. *Clin Infect Dis.* 2013;56:1–10. doi:10.1093/cid/cis966.
- [6] Della Valle C, Parvizi J, Bauer TW, DiCesare PE, Evans RP, Segreti J, et al. American Academy of Orthopaedic Surgeons clinical practice guideline on: the diagnosis of periprosthetic joint infections of the hip and knee. *J Bone Joint Surg Am.* 2011;93:1355–1357. doi:10.2106/JBJS.9314ebo.
- [7] Zmistowski B, Della Valle C, Bauer TW, Malizos KN, Alavi A, Bedair H, et al. Diagnosis of periprosthetic joint infection. *J Arthroplasty.* 2014;29:77–83. doi:10.1016/j.arth.2013.09.040.
- [8] Maurer TB, Ochsner PE. [Infected knee arthroplasty. A treatment algorithm at the Kantonsspital Liestal, Switzerland]. *Orthopade.* 2006;35:917–918. doi:10.1007/s00132-006-0978-y.
- [9] Parvizi J, Gehrke T, Chen AF. Proceedings of the International Consensus on Periprosthetic Joint Infection. *Bone Joint J.* 2013;95-B:1450–1452. doi:10.1302/0301-620X.95B11.33135.
- [10] Alvand A, Grammatopoulos G, de Vos F, Scarborough M, Kendrick B, Price A, et al. Clinical outcome of massive endoprostheses used for managing periprosthetic joint infections of the hip and knee. *J Arthroplasty.* 2018;33:829–834. doi:10.1016/j.arth.2017.09.046.
- [11] Jeys LM, Grimer RJ, Carter SR, Tillman RM. Periprosthetic infection in patients treated for an orthopaedic oncological condition. *J Bone Joint Surg Am.* 2005;87:842–849. doi:10.2106/JBJS.C.01222.
- [12] Harges J, Gebert C, Schwappach A, Ahrens H, Streitburger A, Winkelmann W, et al. Characteristics and outcome of infections associated with tumor endoprostheses. *Arch Orthop Trauma Surg.* 2006;126:289–296. doi:10.1007/s00402-005-0009-1.
- [13] Funovics PT, Hipfl C, Hofstaetter JG, Puchner S, Kotz RI, Dominkus M. Management of septic complications following modular endoprosthetic reconstruction of the proximal femur. *Int Orthop.* 2011;35:1437–1444. doi:10.1007/s00264-010-1054-0.
- [14] Wafa H, Grimer RJ, Reddy K, Jeys L, Abudu A, Carter SR, et al. Retrospective evaluation of the incidence of early periprosthetic infection with silver-treated endoprostheses in high-risk patients: case-control study. *Bone Joint J.* 2015;97-B:252–257. doi:10.1302/0301-620X.97B2.34554.





## 2.4. TREATMENT: TWO-STAGE EXCHANGE

**Authors:** Paul Jutte, Hesham Abdelbary, Claudia Löwik

### QUESTION 1: What factors may improve the outcome of a two-stage exchange arthroplasty in patients with an infected oncologic endoprosthesis?

**RECOMMENDATION:** There are numerous factors that improve the outcome of two-stage exchange arthroplasty in general, and after oncologic reconstruction in particular. These include host-related factors (such as host optimization by treating anaemia, malnutrition, hyperglycemia, immunosuppressive state and so on), organism-related factors (such as administration of appropriate systemic and local antibiotics) and surgery-related factors (such as aggressive debridement of soft tissue and bone, optimal soft tissue management and prevention of postoperative complications).

**LEVEL OF EVIDENCE:** Limited

**DELEGATE VOTE:** Agree: 100%, Disagree: 0%, Abstain: 0% (Unanimous, Strongest Consensus)

#### RATIONALE

Surgical reconstruction using a mega-endoprosthesis after tumor resection can be frequently associated with deep surgical site infection that leads to prosthetic joint infection (PJI). The prevalence of PJI associated with oncologic endoprosthesis is 7-28% compared to only 1-2% in primary joint replacements. Cancer patients are at a higher risk for developing PJI after receiving an endoprosthesis due to numerous risk factors, which lead to local and systemic immunodeficiency. These risk factors include chemotherapy, radiotherapy, prolonged surgical time, increased bleeding, larger implant surface area and compromised soft tissue envelope.

In case of an infected oncologic endoprosthesis, debridement, antibiotics and implant retention (DAIR) can be performed, especially in early acute infections (< 3 months). If DAIR fails to eradicate the infection, a two-stage revision is necessary. In literature, two-stage revision is generally reported as a good surgical approach for infection control with a reported success rate of 63-100% [1-6]. Eradication of infection is generally worse after a single-stage revision and, of course, better after an amputation [4,7-9].

Although various studies assessed infection after oncologic endoprostheses, only a few have specifically evaluated the efficacy of DAIR or two-stage revision [2,3]. The factors associated with infection control in oncologic endoprostheses have been individually discussed. After review of the literature, 41 articles were included in our literature analysis. The most important study characteristics are described in the evidence table.

#### Antibiotics

Little is known about the use of antibiotics in two-stage revision for an infected oncologic endoprostheses. In all studies, antibiotic regimens differed per patient according to culture results and local protocol without specific details being provided. In general, antibiotics should be administered for three months, and the type of antibiotics is decided based on culture results, as well as the consultation with an infectious disease specialist. There are no studies stating that administering antibiotics longer than three months is necessary. Regarding antibiotic prophylaxis, it is recommended to administer prophylactic antibiotics for more than 24 hours, since a systematic review of Racano et al. showed that this reduces the infection rate from 13% to 8% [10]. Regarding the timing for reimplantation after PJI treatment, there is no evidence for the optimal timing other than waiting for completion of chemotherapy before reimplantation [11].

#### Chemotherapy

The influence of chemotherapy can be expected since it down regulates the host defence mechanisms. However, this is not uniformly reported in the assessed studies. Several studies found an increased risk of developing an infection after implantation of an oncologic endoprostheses in patients undergoing chemotherapy [5,11,12]. However, other studies did not confirm this notion [8,13,14]. Because of the immunocompromised status of patients receiving chemotherapy, it is advised to delay reimplantation until after completion of chemotherapy [15].

#### Radiotherapy

Application of radiotherapy increases the risk of infection after oncologic endoprosthesis [7,16]. Grimer et al. and Flint et al. found a higher failure rate in patients who underwent radiotherapy [2,3]. Regarding timing of radiotherapy, postoperative radiation has a bigger influence on the infection rate than preoperative radiotherapy [16]. The success rate of DAIR procedures in which postoperative radiotherapy had been applied was lower. Radiation influences the quality of soft tissue and hampers local defence mechanisms.

#### Microorganisms

The most common microorganisms causing infection of oncological endoprostheses are *Staphylococcus aureus* and coagulase negative staphylococci that account for > 50% of PJI. Many of the documented infections were also polymicrobial infection accounting 21-45% of cases [1,4,7,8,17]. There was no difference between monomicrobial and polymicrobial infections regarding cure rate [4]. A study by Peel et al. demonstrated that the majority of infections were caused by multi-resistant microorganisms [9]. Cure rates for DAIR as well as for two-stage revision after PJI did not show any correlation between the infecting organism and the success of eradicating the infection [2]. It is important to note that the aforementioned results are based on a small number of patients. Therefore, it is difficult to draw firm conclusions that can be generalized to all cases of infection associated with oncologic endoprostheses.

#### Silver-coated Arthroplasty

Few studies have reported on the benefits of using silver-coated endoprostheses to decrease the risk of developing PJI in patients

treated for primary and metastatic bone cancer. Silver cations possess bactericidal properties by disrupting cellular membrane and DNA formation. Donati et al. and Wafa et al. reported a 50% less incidence of PJI in patients treated with silver-coated megaprosthesis compared to uncoated ones [12,18]. In addition, Wafa et al. showed that the success rate of using DAIR as well as two-stage revision to treat infected silver-coated megaprosthesis was significantly higher than when used to treat infected uncoated implants [12]. Zajonz et al. reported that reinfection rate after healed reinfection in the silver group was slightly better than the non-silver group (40 vs. 57%) [19].

Hardes et al. showed that silver levels in the serum were detected up to 24 months post implantation of silver-coated prostheses [20]. Also, there were no reports of toxicity or adverse local tissue reaction in patients treated with silver-coated implants. Despite these promising results, there are only a handful of studies that reported on outcomes after using these coated implants.

## DAIR

The DAIR procedure is one of the treatment approaches described for PJI of endoprostheses in cancer patients. However, treatment outcomes after DAIR are highly variable and unpredictable in an oncology setting. Success rates vary between 39-70% [1,9,12,17,21]. Reported factors that are associated with better outcomes after DAIR include superficial early infection, short duration of symptoms, well-fixed implants and well-characterized microbiology demonstrating a highly susceptible pathogen [13,15,22]. Unfortunately, the studies that reported on DAIR outcomes have a highly variable period of clinical follow-up (34 months-10 years).

## REFERENCES

- [1] Dhanoa A, Ajit Singh V, Elbahri H. Deep infections after endoprosthetic replacement operations in orthopedic oncology patients. *Surg Infect (Larchmt)*. 2015;16:323-332. doi:10.1089/sur.2014.049.
- [2] Flint M, Griffin A, Bell R, Wunder J, Ferguson P. Two-stage revision of infected uncemented lower extremity tumor endoprostheses. *J Arthroplasty*. 2007;22:859-865. doi:10.1016/j.arth.2006.11.003.
- [3] Grimer R, Belthur M, Chandrasekar C, Carter S, Tillman R. Two-stage revision for infected endoprostheses used in tumor surgery. *Clin Orthop Relat Res*. 2002;395:193-203.
- [4] Jeys L, Grimer R, Carter S, Tillman R. Periprosthetic infection in patients treated for an orthopaedic oncological condition. *Journal of Bone and Joint Surgery - Series A* 2005;87:842-9. doi:10.2106/JBJS.C.01222.
- [5] Lee S, Oh J, Lee K, Yoo K, Kim H. Infection after prosthetic reconstruction in limb salvage surgery. *Int Orthop*. 2002;26:179-184. doi:10.1007/s00264-001-0328-y.
- [6] Morii T, Morioka H, Ueda T, Araki N, Hashimoto N, Kawai A, et al. Deep infection in tumor endoprostheses around the knee: a multi-institutional study by the Japanese Musculoskeletal Oncology Group. *BMC Musculoskeletal Disord*. 2013;14:1. doi:10.1186/1471-2474-14-51.
- [7] Funovics P, Hipfl C, Hofstaetter J, Puchner S, Kotz R, Dominkus M. Management of septic complications following modular endoprosthetic reconstruction of the proximal femur. *Int Orthop* 2011;35:1437-1444. doi:10.1007/s00264-010-1054-0.
- [8] Hardes J, Gebert C, Schwappach A, Ahrens H, Streitburger A, Winkelmann W, et al. Characteristics and outcome of infections associated with tumor endoprostheses. *Arch Orthop Trauma Surg*. 2006;126:289-296. doi:10.1007/s00402-005-0009-1.
- [9] Peel T, May D, Buising K, Thursky K, Slavin M, Choong P. Infective complications following tumour endoprosthesis surgery for bone and soft tissue tumours. *Eur J Surg Oncol*. 2014;40:1087-1094. doi:10.1016/j.ejso.2014.02.241.
- [10] Racano A, Pazonis T, Farokhyar F, Deheshi B, Ghert M. High infection rate outcomes in long-bone tumor surgery with endoprosthetic reconstruction in adults: a systematic review. *Clin Orthop Relat Res*. 2013;471:2017-2027. doi:10.1007/s11999-013-2842-9.
- [11] McDonald D, Capanna R, Gherlinzoni F, Bacci G, Ferruzzi A, Casadei R, et al. Influence of chemotherapy on perioperative complications in limb salvage surgery for bone tumors. *Cancer*. 1990;65:1509-1516. doi:10.1002/1097-0142(19900401)65:7<1509::AID-CNCR2820650710>3.0.CO;2-I.
- [12] Wafa H, Grimer R, Reddy K, Jeys L, Abudu A, Carter S, et al. Retrospective evaluation of the incidence of early periprosthetic infection with silver-treated endoprostheses in high-risk patients: case-control study. *Bone Joint J*. 2015;97-B:252-257. doi:10.1302/0301-620X.97B2.34554.
- [13] Mavrogenis A, Pala E, Angelini A, Calabro T, Romagnoli C, Romantini M, et al. Infected prostheses after lower-extremity bone tumor resection: clinical outcomes of 100 patients. *Surg Infect*. 2015;16:267-275. doi:10.1089/sur.2014.085.
- [14] Morii T, Yabe H, Morioka H, Beppu Y, Chuman H, Kawai A, et al. Postoperative deep infection in tumor endoprosthesis reconstruction around the knee. *J Orthop Sci*. 2010;15:331-339. doi:10.1007/s00776-010-1467-z.
- [15] Mavrogenis AF, Papagelopoulos PJ, Coll-Mesa L, Pala E, Guerra G, Ruggieri P. Infected tumor prostheses. *Orthopedics*. 2011;34:991-998. doi:10.3928/01477447-2011021-24.
- [16] Jeys L, Luscombe J, Grimer R, Abudu A, Tillman R, Carter S. The risks and benefits of radiotherapy with massive endoprosthetic replacement. *J Bone Joint Surg Br*. 2007;89-B:1352-1355. doi:10.1302/0301-620X.89B10.19233.
- [17] Manoso M, Boland P, Healey J, Cordeiro P. Limb salvage of infected knee reconstructions for cancer with staged revision and free tissue transfer. *Ann Plast Surg*. 2006;56:532-535. doi:10.1097/01.sap.0000203990.08414.ad.
- [18] Donati F, Di Giacomo G, D'Adamo S, Ziranu A, Careri S, Rosa M, et al. Silver-coated hip megaprosthesis in oncological limb salvage surgery. *BioMed Res Int*. 2016;2016:1-6. doi:10.1155/2016/9079041.
- [19] Zajonz D, Zieme A, Prietzel T, Moche M, Tiepoldt S, Roth A, et al. Periprosthetic joint infections in modular endoprostheses of the lower extremities: a retrospective observational study in 101 patients. *Patient Saf Surg*. 2016;10:1-9. doi:10.1186/s13037-016-0095-8.
- [20] Hardes J, Ahrens H, Gebert C, Streitburger A, Buerger H, Erren M, et al. Lack of toxicological side-effects in silver-coated megaprostheses in humans. *Biomaterials*. 2007;28:2869-2875. doi:10.1016/j.biomaterials.2007.02.033.
- [21] Bus M, Szafranski A, Sellevold S, Goryn T, Jutte P, Brumer J, et al. LUMIC endoprosthetic reconstruction after periacetabular tumor resection: short-term results. *Clin Orthop Relat Res*. 2017;475:686-695. doi:10.1007/s11999-016-4805-4.
- [22] Li X, Moretti V, Ashana A, Lackman R. Perioperative infection rate in patients with osteosarcomas treated with resection and prosthetic reconstruction. *Clin Orthop Relat Res*. 2011;469:2889-2894. doi:10.1007/s11999-011-1877-z.
- [23] Chambers C, Proctor C, Kabler P. Bactericidal effect of low concentrations of silver. *J Am Water Works Assoc*. 1962;54:208-216.
- [24] Felden A, Vaz G, Kreps S, Anract P, Hamadouche M, Biau D. A cemented acetabular component with a reinforcement cross provides excellent medium-term fixation in total hip arthroplasty after pelvic irradiation. *Bone Joint J*. 2015;97-B:177-184. doi:10.1302/0301-620X.97B2.34545.
- [25] Gitelis S, Yergler J, Sawlani N, Schiff A, Shott S. Short and long term failure of the modular oncology knee prosthesis. *Orthopedics*. 2008;31:362.
- [26] Hardes J, von Eiff C, Streitburger A, Balke M, Budny T, Henrichs M, et al. Reduction of periprosthetic infection with silver-coated megaprostheses in patients with bone sarcoma. *J Surg Oncol*. 2010;101:389-395. doi:10.1002/jso.21498.
- [27] Henderson E, Groundland J, Pala E, Dennis J, Wooten R, Cheong D, et al. Failure mode classification for tumor endoprostheses: retrospective review of five institutions and a literature review. *J Bone Joint Surg Am*. 2011;93:418-429. doi:10.2106/JBJS.J.00834.
- [28] Hollinger M. Toxicological aspects of topical silver pharmaceuticals. *Crit Rev Toxicol*. 1996;26:255-260.
- [29] Hsu R, Sim F, Chao E. Reoperation results after segmental prosthetic replacement of bone and joint for limb salvage. *J Arthroplasty*. 1999;14:519-526.
- [30] Jacobs J, Kull L, Frey G, Gitelis S, Sheinkop M, Kramer T, et al. Early failure of acetabular components inserted without cement after previous pelvic irradiation. *J Bone Joint Surg Am*. 1995;77:1829-1835. doi:10.2106/00004623-199512000-00006.
- [31] Jeys L, Grimer R, Carter S, Tillman R. Risk of amputation following limb salvage surgery with endoprosthetic replacement, in a consecutive series of 1261 patients. *Int Orthop*. 2003;27:160-163. doi:10.1007/s00264-003-0429-x.
- [32] Jeys L, Grimer R, Carter S, Tillman R, Abudu A. Post operative infection and increased survival in osteosarcoma patients: are they associated? *Ann Surg Oncol*. 2007;14:2887-2895. doi:10.1245/s10434-007-9483-8.
- [33] Jeys L, Grimer R. The long-term risks of infection and amputation with limb salvage surgery using endoprostheses. *Recent Results Cancer Res*. 2009;179:75-84.
- [34] Kaminski P, Szmyd J, Ambroz J, Jaworski J, Franczuk B. A comparison of outcomes of treatment with resection prosthesis of the hip in revision and oncological surgery. *Ortop Traumatol Rehabil*. 2017;19:145-156.
- [35] Kim K. Uncemented total hip arthroplasty in patients with a history of pelvic irradiation for prostate cancer. *J Bone Joint Surg Am*. 2007;89:798-805. doi:10.2106/JBJS.F.00183.
- [36] Lansdown A. A pharmacological and toxicological profile of silver as an antimicrobial agent in medical devices. *Adv Pharmacol Sci*. 2010;2010:1-16. doi:10.1155/2010/910686.
- [37] Massin P, Duparc J. Total hip replacement in irradiated hips: a retrospective study of 71 cases. *J Bone Joint Surg Br*. 1995;77:847-852.
- [38] Mittermayer F, Windhager R, Dominkus M, Krepler P, Schwameis E, Sluga M, et al. Revision of the Kotz type of tumour endoprosthesis for the lower limb. *J Bone Joint Surg Br*. 2002;84:401-406.
- [39] Pilge H, Gradl G, von Eisenhart-Rothe R, Gollwitzer H. Incidence and outcome after infection of megaprostheses. *Hip Int*. 2012;22:83-90.
- [40] Renard A, Veth R, Schreuder H, van Loon C, Kooops H, van Horn J. Function and complications after ablative and limb-salvage therapy in lower extremity sarcoma of bone. *J Surg Oncol*. 2000;73:198-205. doi:10.1002/(SICI)1096-9098(200004)73:4<198::AID-JSO3>3.0.CO;2-X.
- [41] Sherman S, Cunneen K, Walcott-Sapp S, Brause B, Westrich G. Custom total femur spacer and second-stage total femur arthroplasty as a novel approach to infection and periprosthetic fracture. *J Arthroplasty*. 2008;23:781-786. doi:10.1016/j.arth.2007.05.027.

TABLE 1. Evidence table

Author and Year	Study Type	Patients	Procedures	Follow-up	Major Outcomes
Bus 2017 [21]	Retrospective cohort 2008–2014	N = 47 LUMIC reconstruction for pelvic tumor	* 69% DAIR * 31% implant removal	3-9 years	* 28% had infection. * 69% were successfully treated with DAIR (2). * 31% needed implant removal. Two had amputation, 1 rotationplasty and 1 LUMIC prosthesis. * More blood loss was associated with a higher risk of infection; other factors were not associated.
Chambers 1962 [23]	Narrative review	X	X	X	* Article on the bactericidal effects of silver (1f).
Dhanoa 2015 [1]	Retrospective cohort 2007–2011	N = 105 Endoprosthetic reconstruction for tumor	* 54% DAIR * 46% 2-SR	32 months	* 12.4% infection at 0-63 months. * Higher risk after additional procedures (13x), comorbidity, proximal tibia endoprostheses, pelvic endoprostheses and preoperative hospitalization >48 hour. Lower risk with distal femoral prostheses. * 80% of infections had operations >2.5h, compared to 16.3% in non-infections. * 38% <i>Staph aureus</i> , 31% CNS, 23% <i>Klebsiella pneumoniae</i> , 23% <i>Pseudomonas aeruginosa</i> . 38.5% had polymicrobial infection (1d). * 80% of 2-SR were successful; 1 patient had antibiotic suppression. * 43% of DAIR were successful; 2 patients had antibiotics; 2 patients had amputation (2).
Donati 2016 [18]	Retrospective case-control 2005–2016	N = 68 Megaprosthesis reconstruction for proximal femur tumors	X	47 months (12-114 months)	* Overall infection rate 11.8% at mean 25 months: silver 7.9%, control 16.7% (1f). * In late infection, explanted megaprosthesis had important degradation of the coating surface (1f). * No differences in functional scores between silver and control (1f). * No local or general signs of toxicity (1f).
Felden 2015 [24]	Prospective cohort 1995–2011	N = 45 Pelvic irradiation before cemented THA	X	51 months (17-137 months)	* Patient survival was 71% at 2y, 52% at 5y and 41% at 10y. * The cumulative probability of revision was 2.2% at 1y, 2.2% at 2y, 8.1% at 5y and 20.2% at 10y. * 6% underwent revision for infection, 1 treated with 2-SR, 2 treated with 1-SR (all successful).
Flint 2007 [2]	Prospective cohort 1989–2004	N = 15 Infection after uncemented Kotz prostheses for bone sarcoma	2-SR	42 months (3-150 months)	* Prosthetic infection occurred at mean 28 months (1-132 months). * 75% CNS, 33% <i>Staph aureus</i> , 8% <i>Pseudomonas aeruginosa</i> , 8% <i>E. coli</i> , 8% <i>Streptococcus viridans</i> (1d). * 73% had second-stage revision: 27% had amputation, 73% with infection control after second-stage. * 60% success with retention of diaphyseal stems; 40% success with removal of anchorage pieces. * No relation between success and anatomical location or infecting organism (1d). * 66% of failures had previous radiation (1c). * In case of infection within 6 months 86% of 2-SR was successful, after 6 months only 25%.

TABLE 1. Evidence table (Cont.)

Author and Year	Study Type	Patients	Procedures	Follow-up	Major Outcomes
Funovics 2011 [7]	Retrospective cohort 1982-2008	N = 166 Endoprosthetic reconstruction for tumor	* 83% 1-SR * 8% muscle flap * 8% deceased	47 months (0-365 months)	* Survival rate without infection was 95.9% at 1y, 89.2% at 5y, 89.2% at 10y and 77.8% at 20y. * 7.2% had infection at mean 39 months (0-167 months). * 30% CNS, 30% Staph epidermidis. Polymicrobial infection in 30.8% (1d). * Higher rate of infection in primary tumors, cemented prostheses, pelvic reconstruction, additional operations or radiotherapy (1c). * 63% infection control by 1-SR, 13% additional 1-SR, 25% additional 2-SR.
Gitelis 2008 [25]	No full text	X	X	X	X
Grimer 2002 [3]	Prospective cohort 1989-1998	N = 34 Infection after endoprostheses for sarcoma	2-SR	6-116 months	* Obvious causes of infection included lengthening or rebushing procedures, infected ingrown toenail, chest infection, infected burn blister, infected Hickman catheter and neutropenic septicemia. * 53% CNS, 32% Staph aureus, 6% streptococci, 3% Enterobacter and 3% Corynebacterium (1d). * 70% had infection control after 2-SR. 6% needed amputation within 6 months. 6% needed additional 2-SR (1 successful, 1 not). 18% had late infections with various treatments. * Overall success rate for controlling infection was 94% at 6 months, 91% at 1 year, 74% at 5 years and 65% at 10 years. * Reinfection occurred in all 3 patients with previous radiotherapy (1c). * Functional outcome after successful infection control was mean 77% MSTs (47-100%).
Hardes 2006 [8]	Retrospective cohort 1992-2003	N = 30 Infection after MUTARS tumor endoprostheses for sarcoma	* 3-3% antibiotics * 10% 1-SR * 80% 2-SR	32 months (3-128 months)	* Infection occurred at mean time 16 months (1-70 months). * 62% CNS, 21% Staph aureus, 14% Enterococcus species, 21% had polymicrobial infections (1d). * 1-SR was successful in 33%, 2-SR in 63%. * 33% of 2-SR failures needed amputation, 33% rotationarthroplasty, 11% arthrodesis, 22% retained the spacer (1 died after 4 months, 1 had satisfactory function). * 83% needed a change of spacer (1f). * The most important risk factor for failed limb salvage was poor soft tissue. * Chemotherapy, time of occurrence of infection, virulence and type of infection had no influence (1b). * A mean of 2.6 revision operations per patients, mean duration of hospital stay 68 days.
Hardes 2007 [20]	Prospective cohort 2002-2004	N = 20 Silver-coated MUTARS tumor endoprostheses for metastasis	X	19 months (2-32 months)	* No patients had signs of local or systemic argyrosis (1f). * The mean serum silver concentration was 0.37 ppb preoperatively, 2.80 ppb 2 week postoperatively. Between 2 and 24 months silver concentration varied from 1.93 - 12.98 ppb (1f). * 10 patients showed decreased glomerular filtration rates (1f). * The silver-coating was intact in all patients. Histologic examination showed no signs of chronic inflammation, granulomas or necrotic tissue (1f).

TABLE 1. Evidence table (Cont.)

Author and Year	Study Type	Patients	Procedures	Follow-up	Major Outcomes
Hardes 2010 [26]	Prospective case-control 2005–2009	N = 51 (74 control) Silver-coated replacement for bone or soft-tissue tumors	Various	19 months (3–63 months)	<ul style="list-style-type: none"> <li>* 5.9% with silver had infections compared to 17.6% with titanium prostheses, at mean 11 months (1f).</li> <li>* Patients with infection had longer operating time (305 vs. 228 minutes).</li> <li>* 38.5% with titanium prostheses had amputation or rotationplasty for infection, 0% in silver group (1f).</li> <li>* In the silver group 2 were treated with antibiotics alone, 1 had minor revision (one-stage without removal of the stem), all were successful (1f).</li> </ul>
Henderson 2011 [27]	Retrospective cohort 1974–2008	N = 2,174 Limb preservation with metallic endoprostheses for tumor	X	X	<ul style="list-style-type: none"> <li>* 24.5% were considered failures, of which 12% had soft tissue problems, 19% aseptic loosening, 17% fracture, 17% tumor progression, 34% infection.</li> <li>* Infection occurred more often in hinged prostheses than in polyaxial prostheses (<math>p &lt; 0.05</math>).</li> <li>* Failure incidence decreased over time. The mean time to failure was 47 months.</li> <li>* Literature review of 4359 patients with 29% failures.</li> </ul>
Hollinger 1996 [28]	No full text	X	X	X	
Hsu 1999 [29]	Prospective cohort 1975–1986	N = 38 Limb salvage for tumors needing revision surgery	<ul style="list-style-type: none"> <li>* 50% revision</li> <li>* 32% amputation</li> <li>* 10% arthrodesis</li> <li>* 8% miscellaneous</li> </ul>	51 months	<ul style="list-style-type: none"> <li>* Indications for reoperation were aseptic loosening (34%), instability (13%), infection (13%), tumor recurrence (13%), fracture (11%) and miscellaneous (16%).</li> <li>* 16% died after revision at a mean of 40 months after revision.</li> <li>* After revision functional results were excellent (12.5%), good (81.3%) or fair (6.25%).</li> <li>* 63% had radiolucent zones immediately after revision. 25% of these developed progressive changes that had an effect on limb function.</li> <li>* Patients with revision had higher survival rates and longer disease-free intervals than patients with amputation (<math>p &lt; 0.01</math>).</li> <li>* Overall 18.4% had complications: 5.3% aseptic loosening, 5.3% infection, 2.6% non-union, 2.6% local recurrence and 2.6% instability.</li> </ul>
Jacobs 1995 [30]	Retrospective cohort 1983–1991	N = 9 Uncemented THA with previous pelvic irradiation	X	37 months (17–78 months)	<ul style="list-style-type: none"> <li>* 4/9 radiographic and clinical migrations, 2/4 had revision, of which 1 needed Girdlestone after revision (1c).</li> </ul>

TABLE 1. Evidence table (Cont.)

Author and Year	Study Type	Patients	Procedures	Follow-up	Major Outcomes
Jeys 2003 [31]	Retrospective cohort 1966–2001	N = 1,261 Endoprosthetic replacement	Amputation	5–2 years	<ul style="list-style-type: none"> <li>* Overall patient survival was 60% at 5 years, 54% at 10 years and 40% at 20 years.</li> <li>* Overall limb survival without amputation was excellent with 91% at 20 years.</li> <li>* Overall risk of amputation was 8.9% of which the reasons were local recurrence (63%), infection (34%), mechanical failure (2%) and persistent pain (1%).</li> <li>* Risk of amputation after infection was 19% compared to 36% for local recurrence.</li> <li>* Time to amputation was a mean of 32 months for infection.</li> </ul>
Jeys 2005 [4]	Retrospective cohort 1966–2001	N = 1,240 Prosthetic replacement for bone tumor	<ul style="list-style-type: none"> <li>* 43% 2-SR</li> <li>* 32% amputation</li> <li>* 24% 1-SR</li> <li>* 2% Girdlestone</li> </ul>	5–8 years (0–3–34 years)	<ul style="list-style-type: none"> <li>* 11% had infection from 1996–2001 3.7%, 14% from 1966–1996.</li> <li>* 88% presented within 2 years after the last surgical procedure.</li> <li>* 48% had Staphylococcus epidermidis, 26% had polymicrobial infection (1d).</li> <li>* Polymicrobial infections did not reduce the rate of successful treatment of infection (1d).</li> <li>* Success rates: amputation 98%, 2-SR 72%, Girdlestone 50%, 1-SR 42%.</li> </ul>
Jeys 2007 [32]	Retrospective cohort 1966–2001	N = 412 Endoprosthetic reconstruction for osteosarcoma	X	6–7 years (0–20 years)	<ul style="list-style-type: none"> <li>* 10% had deep infection at mean time 4.6 months.</li> <li>* 52% had Staph epidermidis, 29% Staph aureus (1d).</li> <li>* There was better survival in patients infected with Staphylococcus (10y survival 92%, mixed organisms 79%, no infection 62.2%, Streptococcus 50%) (1d).</li> <li>* There was no evidence that patients with infections had more effective chemotherapy (1b).</li> <li>* There were more infections after radiotherapy (p=0.02) (1c).</li> </ul>
Jeys 2007 [16]	Retrospective cohort 1966–2001	N = 1,254 63 radiotherapy Endoprosthetic replacement for bone tumor	X	5–8 years (0–3–33 years)	<ul style="list-style-type: none"> <li>* Mean postoperative MSTS function score was lower after radiotherapy (64% vs. 81.3%) (1c).</li> <li>* Risk of infection without radiotherapy 9.8%, preoperative radiotherapy 20.7%, postoperative radiotherapy 35.3% (1c).</li> <li>* Risk of amputation without radiotherapy 7.8%, preoperative radiotherapy 17.2%, postoperative radiotherapy 14.7% (1c).</li> <li>* 10y survival was worse after radiotherapy (29%) than without radiotherapy (58%) (1c).</li> </ul>
Jeys 2009 [33]	No full text (chapter book)	X	X	X	X
Kaminsky 2017 [34]	No full text	X	X	X	X

TABLE 1. Evidence table (Cont.)

Author and Year	Study Type	Patients	Procedures	Follow-up	Major Outcomes
Kim 2007 [35]	Prospective cohort 1997–2003	N = 51 Uncemented THA with irradiation of the pelvis for adenocarcinoma of the prostate	X	4.8 years (2–7.5 years)	<ul style="list-style-type: none"> <li>* 47% had radiation induced osteonecrosis of the femoral head (1c).</li> <li>* 6% had wound discharge, which healed without surgical treatment (1c).</li> <li>* 2% had deep infection, which required subsequent resection arthroplasty (successful) (1c).</li> </ul>
Lansdown 2010 [36]	Narrative review	X	X	X	<ul style="list-style-type: none"> <li>* Paper about the mechanisms of absorption and metabolism of silver in the human body, presumed mechanisms of argyria and the elimination of silver-protein complexes in the bile and urine (1f).</li> <li>* Argyria and argyrosis are the principle effects associated with heavy deposition of insoluble silver precipitates in the dermis and cornea/conjunctiva. Argyria is not associated with pathological damage (1f).</li> </ul>
Lee 2002 [5]	Retrospective cohort 1985–1998	N = 145 18 infection Tumor prosthesis for bone and soft tissue tumors	<ul style="list-style-type: none"> <li>* 78% DAIR</li> <li>* 11% 2-SR</li> <li>* 11% 1-SR</li> </ul>	44 months (5–136 months)	<ul style="list-style-type: none"> <li>* 12.4% had infection at mean 8 months (0.5–54 months).</li> <li>* 39% was successfully treated with DAIR or revision; 17% needed arthrodesis and 11% amputation (2).</li> <li>* 100% of 2-SR were successful, 0% of 1-SR were successful.</li> <li>* 33% with uncontrolled infection by DAIR and refused prosthesis removal had suppressive antibiotics.</li> <li>* The knee joint seemed to show poor outcome, but this was not statistically meaningful.</li> <li>* Infection control was poor in cases of cementless fixation (<math>p &lt; 0.01</math>).</li> <li>* Chemotherapy gave a higher risk of infection (18.7% vs. 5.6%) (1b).</li> <li>* Soft tissue defects (sinus, pus discharge, wound dehiscence) correlated with poor prognosis (<math>p &lt; 0.05</math>).</li> </ul>
Li 2011 [22]	Retrospective cohort 1993–2008	N = 53 Endoprosthetic reconstruction for sarcoma	DAIR	10 years	<ul style="list-style-type: none"> <li>* 1.9% had early infection, successfully treated with DAIR (2).</li> <li>* 5.7% had late infections, all treated with DAIR. One was successful, 2 needed revision (successful) (2).</li> <li>* 7.5% had wound complications requiring repeat surgery (debridement and closure) (2).</li> </ul>
Manoso 2006 [17]	Retrospective cohort 1990–2001	N = 11 Infected knee reconstruction after limb-salvage surgery for cancer treated with staged protocol	Staged reconstruction protocol	X	<ul style="list-style-type: none"> <li>* 82% had chronic infection, with a sinus tract in 45% at mean time 6 months (1–210 months).</li> <li>* 45% had failed DAIRs (2).</li> <li>* 55% had Staph aureus, 27% had Staph epidermidis. In 55%, a single organism caused the infection (1d).</li> <li>* 82% were immunocompromised with the administration of chemotherapy at the time of infection (1b).</li> <li>* All limbs were spared without amputation or flap loss. Overall cure rate was 91%.</li> <li>* Early complications were 2 peroneal palsies and 1 venous flap congestion requiring wound revision.</li> <li>* The mean functional outcome was 23/30 and mean knee range of motion 98 degrees.</li> </ul>

TABLE 1. Evidence table (Cont.)

Author and Year	Study Type	Patients	Procedures	Follow-up	Major Outcomes
Massin 1995 [37]	Excluded	X	X	X	X
Mavrogenis 2015 [13]	Retrospective cohort 1983-2010	N = 1,161 Megaprosthesis reconstruction after limb salvage surgery for sarcoma	* 83% 2-SR * 12% 1-SR * 5% amputation	Mean 9 years (3-20 years)	* 8.6% had infection at mean time 3.7y. * Most common isolates were Staph epidermidis (47%), Staph aureus (19%) and pseudomonas (6%) (1d). * Overall survival rate of megaprosthesis was 88% at 10y and 84% at 20y. * Survival was higher for cementless reconstruction, not different for type of megaprosthesis, site of reconstruction or adjuvant therapy (1b).
Mavrogenis 2011 [15]	Narrative review	X	X	X	* DAIR may be effective in early infections, with short duration of symptoms, well-fixed implants and ideally with well-characterized microbiology demonstrating a highly susceptible pathogen (2). * Success in 2-SR 72-91%, 1-SR 42% and amputation 98-100%. * 2-SR is recommended for persistent infections, antibiotic-resistant pathogens or failed 1-SR. In well-fixed cementless modular prostheses anchorage stems can be retained. * Disadvantages of 2-SR are long hospitalization, increased bone loss, disuse osteoporosis, difficult revision operations and shortening of the affected limb. * Reimplantation should be delayed after completion of chemotherapy (1b). * An antibiotic-loaded cement spacer is essential in 2-SR; added antibiotics should be heatstable (1e). * Most surgeons administer systemic antibiotics 6 weeks, with reimplantation after > 2 months (1a).
McDonald 1990 [11]	Retrospective cohort 1970-1986	N = 304 271 malignant 33 benign Prosthesis or non-biological spacer in limb salvage surgery for primary bone tumors	X	2 years	* 11.8% had infection, 22% of these patients needed amputation. * Adjuvant and neo-adjuvant chemotherapy gave a higher risk of complications (32.8% and 55.4% vs. 25.2%). Reconstruction with uncemented prostheses had fewest complications (1b).
Mittermayer 2002 [38]	Excluded	X	X	X	X
Morii 2010 [14]	Retrospective cohort 2000-2008	N = 82 Endoprosthetic reconstruction for knee tumors	X	52 months (9-105 months)	* 17% had infection at mean time 10.9 months. * 50% had Staph aureus, 30% Staph epidermidis and 10% Pseudomonas (1d). * Age, sex, tumor origin, co-morbidities, operating time, blood loss, chemotherapy, clean air operating room, extracapsular resection, prosthesis type, number of postoperative antibiotics, posterior muscle flap were not risk factors for infection (1b). * Skin necrosis and surface infection were risk factors for infection.



TABLE 1. Evidence table (Cont.)

Author and Year	Study Type	Patients	Procedures	Follow-up	Major Outcomes
Morii 2013 [6]	Retrospective cohort 1995–2009	N = 388 Endoprosthetic reconstruction for knee tumors	* 45% debridement * 14% 2-SR * 10% amputation * 9% 1-SR * 7% soft tissue flap	66 months (5-213 months)	* 14.6% had infection at mean time 13 months. * 47% Staph aureus and 17.5% Staph epidermidis (1d). * Infections were controlled in 84.2% the others had an accepted fistula or suppressive antibiotics. * Patients with diabetes, bone metastasis, lack of gastrocnemius flap coverage and pus required more surgical interventions for infection control. * The most successful therapy was 2-SR (80% success). Therapies with prosthesis removal were more successful than other therapies.
Peel 2014 [9]	Retrospective cohort 1996–2010	N = 121 Tumor endoprostheses surgery	* 53% DAIR * 24% 2-SR * 12% 1-SR * 6% resection * 6% amputation	34 months (17-80 months)	* 14% had infection at median time 18 months * Parenteral antibiotics median 9 days (0-58), 82% received oral combination antibiotic therapy with rifampicin (365 days) (1a). * Success rates: DAIR 75%, 1-SR 100%, 2-SR 50%, resection 0%, amputation 100% (2). * The majority of treatment failures occurred in patients with multi-resistant organisms (1d).
Pilge 2012 [39]	No full text	X	X	X	X
Racano 2013 [10]	Systematic review 1990–2011	N = 4,838 in 48 level IV studies	X	X	* Pooled infection rate was 10% (0-25%). * Most common organisms were Staph aureus and Staph epidermidis (1d). * There is considerable variation in antibiotic regimens. 0-24 hour antibiotic prophylaxis had 13% infection, >24 hour prophylaxis had 8% infection (p < 0.05) (1a).
Renard 2000 [40]	Prospective cohort 1975–1995	N = 77 Limb saving surgery (50) or ablative surgery (25) for sarcoma	X	97 months (28-271 months)	* 6% had deep infection, leading to amputation in 2/3 cases. * 4% had superficial infection successfully treated with DAIR and gentamicin beads (2).
Sherman 2008 [41]	Excluded	X	X	X	X
Shin 1999 [42]	Retrospective cohort 1970–1990	N = 52 41 malignant 11 benign Limb salvage surgery for musculoskeletal tumor	* 67% revision * 21% amputation * 8% arthrodesis * 2% fibular graft * 2% ORIF	12 years (37-296 months)	* 11.5% had infection. * Functional rating was 63%. Pain 69%, function 53%, emotional acceptance 72%, support 60%, walking ability 62%, gait: 54%, hand positioning 66%, manual dexterity 94% and lifting ability 63%. * After revision 33% needed reoperation for complications: 58% aseptic loosening, 25% infection, 17% prosthetic failure and 8% patellar dislocation. * Survival after reoperation was 79% (5y) and 65% (10y).

TABLE 1. Evidence table (Cont.)

Author and Year	Study Type	Patients	Procedures	Follow-up	Major Outcomes
Sim 2007 [43]	Retrospective cohort 1996 – 2005	N = 50 Endoprosthetic reconstruction for knee tumors (GRMS)	3 washouts	24.5 months (2-124 months)	<ul style="list-style-type: none"> <li>* Patients with metastatic disease or pathological fractures did not have higher complication rates.</li> <li>* 12% had deep infection for which patients received multiple washouts and long-term antibiotics (2).</li> <li>* 1/6 had revision; 1/6 had amputation (2).</li> </ul>
Wafa 2015 [12]	Prospective case-control 2006–2011	N = 170 Reconstruction with silver-enhanced endoprostheses for several indications	X	12 months	<ul style="list-style-type: none"> <li>* 11.8% infection in silver group, 22.4% in control group (1f).</li> <li>* Higher incidence of Pseudomonas in the silver group (1d/1f).</li> <li>* 70% of infected prosthesis was successfully treated with DAIR, 31.6% in the control group (1f/2).</li> <li>* 15.3% required implant removal, amputation or antibiotic suppression, 3.5% in the silver group (1f).</li> <li>* 18.8% with adjuvant chemotherapy developed infection (1b).</li> <li>* 15% had relapse infection after 2-SR in the silver group, 42.9% in the control group (1f).</li> </ul>
Wirganowicz 1999 [44]	Prospective cohort 1980–1995	N = 64 Failed endoprostheses for neoplastic disease	<ul style="list-style-type: none"> <li>* 75% revision</li> <li>* 25% amputation</li> </ul>	2 years	<ul style="list-style-type: none"> <li>* 13% failed because of an infection.</li> <li>* 50% of infected prostheses had revision with the same prosthesis, 25% with a different prosthesis and 25% underwent amputation.</li> <li>* Patients receiving revision endoprostheses were not at increased risk for a subsequent revision or amputation compared to primary endoprostheses reconstruction.</li> </ul>
Zajonz 2016 [19]	Retrospective cohort 1994–2014 Excluded	N = 34 Modular endoprostheses of the lower extremity for infection	X	72 months (6-267 months)	<ul style="list-style-type: none"> <li>* Reinfection rate after healed reinfection in silver group was 40%, in the non-silver group 57% (1f).</li> </ul>
Zajonz 2017 [45]	Retrospective cohort 1994–2011	N = 101 45 tumor Modular endoprostheses of the lower extremity	<ul style="list-style-type: none"> <li>* 62% 2-SR</li> <li>* 11% resection</li> <li>* 11% arthrodesis</li> <li>* 8% DAIR</li> <li>* 8% amputation</li> </ul>	27 months (5-179 months)	<ul style="list-style-type: none"> <li>* 17.7% had infection (3 early infections, 16 late infections), reinfection rate 37%.</li> <li>* 36.6% CNS, 26.3% Staph epidermidis, 15.8% Staph aureus (1d).</li> <li>* Patients with infection had same age and sex, but higher BMI.</li> <li>* Prosthesis for tumors had fewer infections than other indications (8.9% vs. 21.7%).</li> </ul>

- [42] Shin D, Weber K, Chao E, An K, Sim F. Reoperation for failed prosthetic replacement used for limb salvage. *Clin Orthop Relat Res.* 1999;358:53-63.
- [43] Sim I, Tse L, Ek E, Powell G, Choong P. Salvaging the limb salvage: management of complications following endoprosthetic reconstruction for tumours around the knee. *Eur J Surg Oncol.* 2007;33:796-802. doi:10.1016/j.ejso.2006.10.007.
- [44] Wirganowicz P, Eckardt J, Dorey F, Eilber F, Kabo J. Etiology and results of tumor endoprosthesis revision surgery in 64 patients. *Clin Orthop Relat Res.* 1999;358:64-74.
- [45] Zajonc D, Birke U, Ghanem M, Prietzel T, Josten C, Roth A, et al. Silver-coated modular megaendoprostheses in salvage revision arthroplasty after peri-implant infection with extensive bone loss - a pilot study of 34 patients. *BMC Musculoskelet Disord.* 2017;18:1-7. doi:10.1186/s12891-017-1742-7.

● ● ● ● ●

**Authors:** Muhammad Ather Siddiqi, A. Mazhar Tokgözoğlu

## QUESTION 2: What is the best reconstruction technique for an infected allograft?

**RECOMMENDATION:** The best reconstruction technique for an infected allograft is resection of the infected allograft and reconstruction (preferable two-stage) with an endoprosthesis.

**LEVEL OF EVIDENCE:** Moderate

**DELEGATE VOTE:** Agree: 93%, Disagree: 0%, Abstain: 7% (Super Majority, Strong Consensus)

### RATIONALE

Use of allograft in the reconstruction of a massive bone defect created by resection of a tumor is frequently successful. However, as with all tumor reconstruction methods, it is also plagued with complications, infection being one of them. A number of observational studies have been published on the subject. The largest case series by Mankin et al. described 121 allograft infections in 945 patients accounting to an infection rate of 12.8% [1]. The study did not, however, address management of the infected allograft. A more recent systematic review by Aponte et al. [2] reviewed the available literature and infection rates reported in previous studies [3-7]. The infection rate of allograft used after tumor resection ranged from 8.5% to 13.3%. The infection rate in their own series was 9% with 60 infections in 673 patients who received massive allografts after oncological resections. Only 18% (11/60) of the patients in that cohort were successfully treated by debridement and antibiotics with salvage of the original allograft. Of the 41 patients who underwent two-stage revision, 24 were revised with allograft and 17 with endoprostheses. Reinfection occurred in 14 patients of which 12 were in the allograft group and 2 were in the endoprostheses group. This demonstrated a lesser rate of reinfection when revision to endoprostheses was done as opposed to revision to another allograft.

Our search did not find any reports of revision to a vascularized fibular autograft or treatment with bone transport. Although these are both biological methods of reconstruction and their efficacy in

the treatment of bone defects created by trauma and infection as well as for primary reconstruction following tumor resection is well established [8,9].

### REFERENCES

- [1] Mankin HJ, Hornicek FJ, Raskin KA. Infection in massive bone allografts. *Clin Orthop Relat Res.* 2005;210-216.
- [2] Aponte-Tinao LA, Ayerza MA, Muscolo DL, Farfalli GL. What are the risk factors and management options for infection after reconstruction with massive bone allografts? *Clin Orthop Relat Res.* 2016;474:669-673. doi:10.1007/s11999-015-4353-3.
- [3] Hernigou P, Delepine G, Goutallier D. [Infections after massive bone allografts in surgery of bone tumors of the limbs. Incidence, contributing factors, therapeutic problems]. *Rev Chir Orthop Reparatrice Appar Mot.* 1991;77:6-13.
- [4] Lord CF, Gebhardt MC, Tomford WW, Mankin HJ. Infection in bone allografts. Incidence, nature, and treatment. *J Bone Joint Surg Am.* 1988;70:369-376.
- [5] Loty B, Tomeno B, Evrard J, Postel M. Infection in massive bone allografts sterilised by radiation. *Int Orthop.* 1994;18:164-171.
- [6] Tan MH, Mankin HJ. Blood transfusion and bone allografts. Effect on infection and outcome. *Clin Orthop Relat Res.* 1997;207-214.
- [7] Tomford WW, Thongphasuk J, Mankin HJ, Ferraro MJ. Frozen musculoskeletal allografts. A study of the clinical incidence and causes of infection associated with their use. *J Bone Joint Surg Am.* 1990;72:1137-1143.
- [8] Eward WC, Kontogeorgakos V, Levin LS, Brigman BE. Free vascularized fibular graft reconstruction of large skeletal defects after tumor resection. *Clin Orthop Relat Res.* 2010;468:590-598. doi:10.1007/s11999-009-1053-x.
- [9] Tsuchiya H, Tomita K. Distraction osteogenesis for treatment of bone loss in the lower extremity. *J Orthop Sci.* 2003;8:116-124. doi:10.1007/s007760300020.



**Authors:** John Abraham, Joseph Benevenia, John Strony, Keenan Sobol

### QUESTION 3: What is the best surgical treatment for management of a chronically infected oncologic endoprosthesis? Does this change if the patient is receiving or has received recent chemotherapy and/or irradiation?

**RECOMMENDATION:** We recommend a two-stage revision in the management of a chronically infected oncologic endoprosthesis; however, we acknowledge that support for a one-stage exchange is increasing. There is no study to suggest that this recommendation should change if the patient is receiving or has received recent chemotherapy and/or irradiation.

**LEVEL OF EVIDENCE:** Limited

**DELEGATE VOTE:** Agree: 93%, Disagree: 0%, Abstain: 7% (Super Majority, Strong Consensus)

#### RATIONALE

Although the use of an endoprosthesis in the treatment of musculoskeletal tumors has many advantages, infection of the endoprosthetic device is a significant complication. In addition to eradicating the infection, the goal in treating these infections is to salvage the limb and avoid amputation. There are numerous interventions used in the management of an endoprosthetic infection, including irrigation and debridement, one-stage revision, two-stage revision and amputation as a last resort.

Jeys et al. demonstrated that two-stage revision was able to eradicate infection in 42 of 58 patients (72%), compared to a 47% (15 of 32) success rate with one-stage revision and a 6% (4 of 68) success rate with local surgical debridement with or without antibiotics [1]. Morii et al. reinforce the idea that two-stage revisions have better outcomes compared to both a one-stage exchange and irrigation and debridement [2]. Finally, investigators in Malaysia reported an 80% success rate with two-stage revision compared to a 42.8% success rate with surgical debridement without a change of the implant [3].

In addition to greater success rates, two-stage revision has demonstrated greater functional outcomes. Grimer et al. assessed the functional outcome of patients with a successful two-stage revision using the Musculoskeletal Tumor Society functional evaluation score. The scores ranged from 47% to 100% with a mean of 77% [4]. One study reviewed one-stage exchange which demonstrated a 77.8% success rate and suggested that one-stage revision of infected mega-

prostheses without exchange of anchorage components is a sensible and useful choice for patients with antibiotic-sensitive microorganisms [5].

Given these results, we have concluded that two-stage revision is currently more supported by literature as a surgical treatment for the management of a chronically infected oncologic endoprosthesis. However, due to the presence of some conflicting data, the strength of this recommendation is limited, and we do believe that one-stage exchange with or without exchange of anchorage components may represent a feasible option.

#### REFERENCES

- [1] Jeys LM, Grimer RJ, Carter SR, Tillman RM. Periprosthetic infection in patients treated for an orthopaedic oncological condition. *J Bone Joint Surg Am.* 2005;87:842-849. doi:10.2106/JBJS.C.01222.
- [2] Morii T, Morioka H, Ueda T, Araki N, Hashimoto N, Kawai A, et al. Deep infection in tumor endoprosthesis around the knee: a multi-institutional study by the Japanese Musculoskeletal Oncology Group. *BMC Musculoskelet Disord.* 2013;14:51. doi:10.1186/1471-2474-14-51.
- [3] Dhanoa A, Ajit Singh V, Elbahri H. Deep infections after endoprosthetic replacement operations in orthopedic oncology patients. *Surg Infect.* 2015;16:323-332. doi:10.1089/sur.2014.049.
- [4] Grimer RJ, Belthur M, Chandrasekar C, Carter SR, Tillman RM. Two-stage revision for infected endoprostheses used in tumor surgery. *Clin Orthop Relat Res.* 2002:193-203.
- [5] Holzer G, Windhager R, Kotz R. One-stage revision surgery for infected megaprotheses. *J Bone Joint Surg Br.* 1997;79:31-35.

